

# Clinical Aid in Pediatric Dentistry: Techniques of Band Stabilisation in Impression

Prabhawati P I<sup>1</sup>, Sangeetha P<sup>2</sup>

<sup>1</sup>Reader, Department of Pedodontics Al Ameen Dental College, Bijapur-586301, Karnataka, India.

<sup>2</sup>Assistant Professor, Dept of Pedodontics, M.R. Ambedkar Dental College, Bangalore-5, Karnataka, India.

Corresponding Author: Prabhawati P I

Received: 12/03/2016

Revised: 19/03/2016

Accepted: 31/03/2016

## ABSTRACT

Space maintainers, habit breaking appliances, myofunctional appliances etc, have been used in pediatric dentistry for many years. Bands and wires have been used in their construction. Orthodontic bands are adapted around the tooth and impression is made to pour the work model on which the appliance is fabricated. The fitting of orthodontic bands at the chair side and the transfer of these bands to the impression influences the fit and function of the preventive or interceptive orthodontic appliance being fabricated. Therefore accurate band placement in the impression plays a very important role. This manuscript describes various techniques of orthodontic band stabilization in the alginate impression and discusses their merits and demerits.

**Key words:** orthodontic bands, molar bands, securing bands, impression techniques, sticky wax, stabilizing, space maintainer.

## INTRODUCTION

Preventive and interceptive appliances employ bands and wires in their construction. Orthodontic bands are adapted around the tooth and the impression is made. The bands are transferred to the impression and stabilized. Dental stone is poured to form the work model on which the appliance is fabricated.

The stabilization of bands on impression is a very important step. [1] Many techniques have been employed to stabilize orthodontic bands in their precise positions to ensure proper indirect construction of an appliance on the working cast. Although sticky wax has traditionally been used to lute the bands in key positions, it may not always provide adequate adhesion, especially in a wet environment such as alginate impression. [2] This paper describes various techniques of band stabilization in

alginate impression with their merits and demerits.

## TECHNIQUES

### 1) Direct Method

- 1. Orthodontic wires:** Short sections of 0.020" stainless steel wires have been used to stabilize the bands into the impression material. After separating the cast from the impression, but before appliance fabrication the protruding wires were trimmed from the model with a wire cutter. [2,3]
- 2. Sticky wax:** Sticky wax has been used for reinforcing the position of the band. Hot "sticky wax" was dripped over the bands seated in the alginate, which in turn captures and holds the bands during the pouring of the stone. [3-5]
- 3. L-shape orthodontic wire:** L-shaped 0.032" wires were placed across the teeth from buccal to lingual to secure the

band in the impression. The stone should not be poured, but painted over the impression with a brush and the final fill was done with a spatula. A disc was then used to cut the protruding ends of the wires to flush with the model. [6]

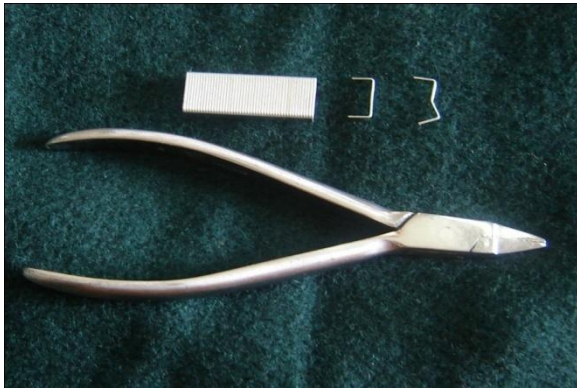


Fig. 1a: Customized stapler pins

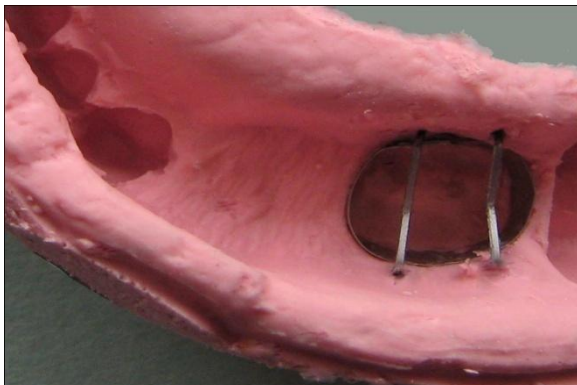


Fig 1b: Alginate impression showing the stabilization of molar bands using stapler pins



Fig 1c: Cast poured after band stabilization

**4. Stapler pins:** This was an excellent technique for securing bands in an impression. Staples were customized and inserted (buccal to lingual) into the alginate impression just over the exposed edges of the bands. Tweezers were used to place two stapler pins per

band over the mesial and distal third to avoid band rotation. (Refer figure 1)

**5. Bobby pins:** These can be used to stabilize orthodontic bands in alginate impressions. A perforated impression tray is a prerequisite for this technique. Two bobby pins were used such that they were placed diagonally on the band. The pins should pass through the buccal side of the tray perforations, running through the set alginate impression material (buccal to lingual) bisecting the band to form an 'X'. It would be best if the pins exit through the lingual side of the tray perforations for added band stability. Dental stone is poured. The bobby pins are removed before the final set of the dental stone. (Refer figure 2)

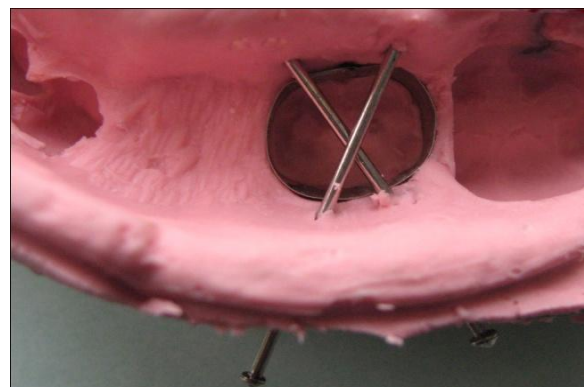


Fig 2a: Alginate impression showing the stabilization of molar bands using bobby pins

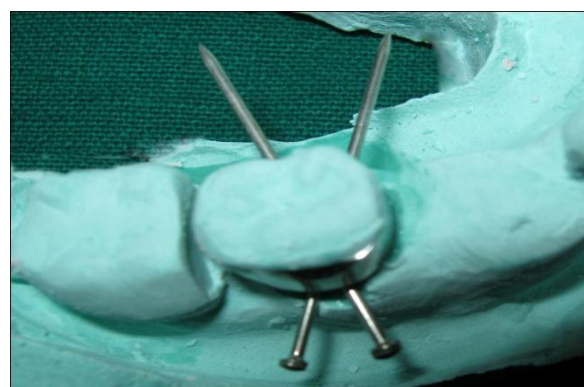

Fig 2b: Cast poured after band stabilization

**6. Super Glue Technique:** A simple and reliable method is to apply a drop of glue at the mesial and distal margins of the orthodontic band where it contacts the impression material. Super Glue

works well as it adheres to the band and to the alginate. But Elaikim Misrahi recommends placing a drop of super glue (cyanoacrylate) on the lingual aspect of the band in contact with the impression material. This glue is known to set rapidly, when it comes in contact with moisture. [2,3]

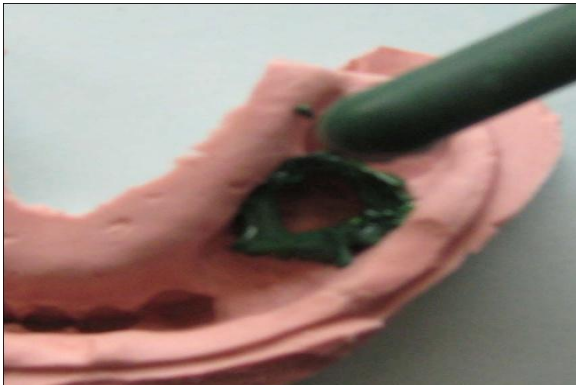


Fig 3a: Adding green stick to stabilize the bands




Fig 3b: Spreading the green stick to the impression flanges using lacrons carver

**7. Green stick compound:** The wet impression was dabbed dry with cotton in the area of band placement. Green stick compound was softened over a flame and flown over the circumference of the band. Wax spatula was heated and was used to spread the compound over the flanges of the impression (buccal and lingual). The heated spatula was run through the inner surface of the band to merge the compound with the band. Blow torch was used such that the surface of the compound gets a smooth finish. The impression was then washed in running tap water so that the compound hardens. Dental stone was poured and the set working model was

immersed in hot water. The softened green stick compound surrounding the band was removed with a lacron carver. (Refer figure 3)

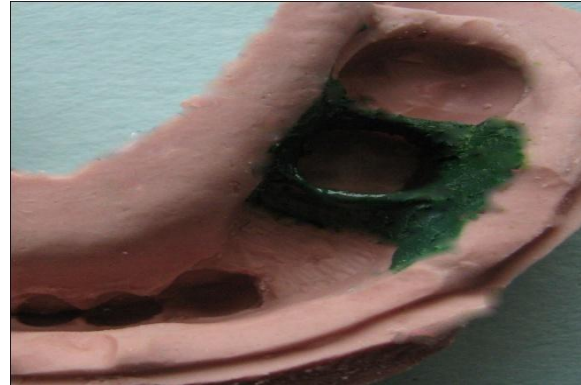

Fig 3c: Alginate impression showing the stabilization of molar bands using green stick compound

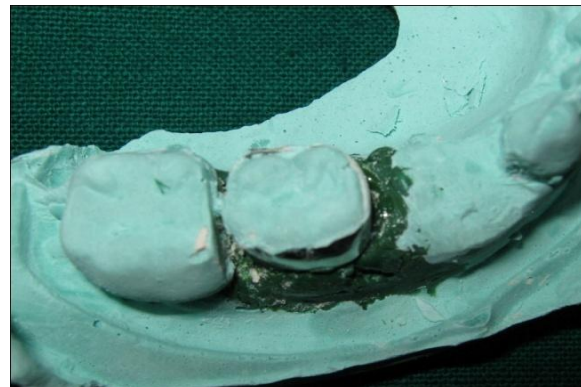

Fig 3d: Cast poured after band stabilization

## II) Indirect Method:

- a) **Method 1:** Orthodontic bands were sized and seated in the mouth. The bands were removed prior to making an impression. The impression and bands were sent to the dental laboratory. The dental technician relieves the model in the appropriate areas. The bands are re-seated accordingly to make the appliance.
- b) **Method 2:** In this method the clinician sends only the impression to the laboratory. Preparation of the model, band sizing and fitting is done on the work model by the lab technician in the dental laboratory. Slightly thicker bands than the conventional orthodontic bands were used for a stronger final appliance.



## DISCUSSION

A fundamental pre-requisite for the construction of satisfactory indirect restorations is the ability to record an accurate and detailed impression of the dental structures.<sup>[8]</sup> In the construction of certain appliances, such as lingual arch or rapid maxillary expansion appliances etc impressions are taken over bands fitted to molar/ premolar teeth. These bands are then placed in the impression prior to pouring the work model.<sup>[7]</sup> The band stabilization has to be done very carefully, as it is possible for these bands to become dislodged when the dental stone is poured. Knowledge of the merits and demerits of various band stabilization methods would help the clinician to choose a suitable technique.

When orthodontic wires are used for band stabilization, the wire segment has to be positioned passively because an active wire can push the band deeper into the impression affecting the fit of the finished appliance.<sup>[2]</sup> Another problem we see with this technique is that when the bands are not completely secured with the wires. The bands tend to rotate during the pouring process, causing an inaccurate final model.

The main problem with the sticky wax is that the wax does not really adhere well to alginate. When the stone was poured and the impression was shaken, the bands tended to shift.<sup>[9]</sup> Without good adhesion, any slight over-vibration during the pouring process will allow the band (or crown) to move out of position. Unfortunately, this is usually discovered after the stone has dried and the patient has left the office.<sup>[5]</sup> According to Stuart La Kind the L-shaped wire technique produces a more accurate duplication, and the laboratory is able to fabricate a well- fitting appliance.<sup>[6]</sup>

Lisenby and Bowman found that too much of glue was a disadvantage. The excess glue if not cleaned from the final model could contaminate the solder joint area as the metal is heated. Thus only a small amount of super glue has to be used on each band.<sup>[2]</sup>

The advantages of bobby pins are that they are readily available, sturdy, easily placed and less time consuming. A single bobby pin can be used for band stabilization like the sectional orthodontic wire, but for added stability we used two bobby pins diagonally to form an 'X' in order to prevent band rotation. Care should be taken to place them passively, as an active pin would tend to push the band gingivally. Bobby pins were placed through the tray perforation, so failure to remove the bobby pin before the final setting time of the dental stone could result in broken cast, when separating the cast from the impression.

The stapler pins are a good alternative to bobby pins. It is very easy to place them on the bands to be secured. These pins are inserted onto the alginate itself unlike the bobby pins which has to pass through the tray perforations. So these pins can be used for band stabilization even when non perforated impression trays are used.

Use of the green stick compound for securing bands in the impression is a very effective method. The bands have a very minimal chance of displacement. But this is an elaborate procedure unlike the other methods of securing band to the impression.

The indirect techniques of band placement do not require the practice of pouring an impression holding the bands. Indirect techniques avoid many of the variables associated with bands moving in the impression and can save considerable office time. Another advantage with this method is that the patient does not have to go through the band placement procedure. After making the impression the patient can come in directly for getting the appliance.

Though there are different techniques for securing the band in the impression, the ultimate decision to use those lies with the individual. Whatever may be the method used, the main aim should be to transfer the bands with minimal displacement, such that the final result would be an appliance with a good and precise fit.

## CONCLUSION

A variety of techniques can be employed in different situations, each of which can be highly successful. But attention should be paid to the details of their execution and the clinician should be aware of their individual limitations and pitfalls. When mistakes occur, clinicians must judge the cause and prevent them. These measures will lead to greater success.

## REFERENCES

1. Nayak UA, Loius J, Sajeev R, Peter J. Band and loop space maintainer - Made easy. *J Indian Soc Ped Prev Dent* Sept 2004; 22(3): 134-6.
2. Lisenby WC, Bowman SJ. Accurate band positioning in impressions. *J Clin Orthod* 2002 Sept; 36(9): 500.
3. Berg JH, Lin JY. Achieving predictable results with space maintainers for children using a novel alginate alternative. *Inside dentistry* 2005 Dec (cited april 27 2009); 68: available at <http://www.dentalaegis.com/Publication> s/Inside\_Dentistry/article.aspx?id=34383.
4. Upadhyay M, Yadav S, Patil S, Keluskar KM. Easy to bond Lingual Retainers. *J Orthod* 2007 Mar; 34(1) 12-15.
5. Forttini A, Franchi L. The first class appliance. In Papadopoulos MA. *Orthodontic treatment of class II non compliant patient. Current principles and techniques.* Elsevier Health Sciences, Chapter 22 2006; 312.
6. La kind SD. Technique Clinic. Securing Bands to an Alginate Impression. *J Clin Orthod* 1993 Feb; 27(2):82.
7. Mizrahi E. Orthodontic auxiliaries. In *Orthodontic pearls. A selection of practical tips and clinical expertise.* Taylor and Francis Group, London UK Chapter 9 2004; 111.
8. Stewardson DA. Trends in indirect dentistry: 5. Impression materials and techniques. *Dent Update.* 2005 Sep; 32(7):374-6, 379-80, and 382-4
9. Tiebout LA. Direct / indirect band placement. *J Dent Technol.* 1998 Jun; 15(5):11-2.

How to cite this article: Prabhawati PI, Sangeetha P. Clinical aid in pediatric dentistry: techniques of band stabilisation in impression. *Int J Res Rev.* 2016; 3(4):7-11.

\*\*\*\*\*