

Original Research Article

Treatment of Unstable Intertrochanteric Fractures Using Dynamic Hip Screws - A Prospective Study

Agarkar Prashant Pradeep¹, Qureshi Faisal², Naik Lokesh Gudda³,
Sharma Gaurav Mahesh², Badgire Krishna Sudhakar²

¹M.S. Orthopaedics, Consultant, Nanavati Hospital, Mumbai

²M.S. Orthopaedics, ³D. Ortho, DNB Ortho,

Clinical Associate, Sir HN Reliance Foundation Hospital, Prarthana Samaj, Raja Ram Mohan Roy Road,
Girgaon-400004, Mumbai, Maharashtra, India.

Corresponding Author: Sharma Gaurav Mahesh

ABSTRACT

Introduction- Treatment of Unstable Intertrochanteric fractures by Dynamic hip screws is a gold standard followed now. The aim of the present study was to analyze the efficacy, benefits and overall outcome of such fractures treated with DHS.

Materials and Methods- 30 fractures with unstable intertrochanteric fractures were treated between February 2014 and December 2014. The inclusion criteria were skeletally matured patients with unstable intertrochanteric fractures. Patients with stable intertrochanteric fractures, medically unfit patients and old malunited fractures were excluded from the study. All the fractures were classified using Evans classification system.

Results- The mean age was 66.2 years. Accidental fall was the most common mechanism of injury in 23 (77%) cases. As per the Evan's classification system, there were 10 (32%) cases of type III, 13 (44%) and 7 (24%) cases of type IV and V respectively encountered in the present study. Average duration of surgery was 51±14.2 mins. Radiological union was observed in 66.7% by 14 weeks. A shortening of 2 cms was observed in 8 (27%) cases. Final outcome was assessed using the Salvati Wilson scoring system. 21 (70%) cases had excellent, 4 (13.33%) cases had good, 3 (10%) cases had fair and 2 (6.67%) cases had poor results respectively. **Conclusion-** The dynamic hip screw with a barrel side plate has the advantage in that it allows controlled concentric collapse at the fracture site even in osteoporotic bone.

Keywords- Hip fractures, Intertrochanter fractures, Dynamic hip screws.

INTRODUCTION

The impact Hip fractures of goes far beyond immediate clinical considerations and extends into the domains of medicine, rehabilitation, psychiatry, social works and medical economics. [1]

Proximal femur fractures are divided into three categories: femoral neck and intertrochanteric fractures account for 90%, subtrochanteric fractures occurring in 5-10%. [2] Intertrochanteric fractures are around four times more frequent than other fractures of the proximal femur and are a

usual occurrence in older patients above 65 years of age, when there is far greater loss of skeletal mass. Unlike neck femur fractures, these fractures unite readily with conservative line of treatment with unavoidable complications like mal-union with coxa-vara deformity resulting in shortening of the limb. [3] Surgical treatment allows early ambulation and thus avoids the devastating complications. Variety of fixation devices have been used till date to treat these notorious injuries which involve sliding hip screws, intramedullary devices

like gamma nail and proximal femoral nail. Dynamic Hip screw (DHS) permits the proximal fragment to collapse in a controlled and concentric manner, thereby seeking its own position of greatest stability. It has stood the test of time and is still considered to be the treatment of choice.

The aim of the present study was to analyze the efficacy, benefits and overall outcome of the Dynamic Hip Screw in treating unstable intertrochanteric fractures.

MATERIALS AND METHODS

30 fractures with unstable intertrochanteric fractures were treated between February 2014 and December 2014

at a tertiary care hospital. The inclusion criteria were skeletally matured patients with unstable intertrochanteric (Evan's type 3, 4 and 5) fractures. Patients with stable intertrochanteric fractures, medically unfit patients and old malunited fractures were excluded from the study. All the fractures were classified using Evans classification system. Well written informed consent was obtained from all the patients. All the necessary haematological and radiological work-up (Fig. 1) was done for all the patients. Prior ethical committee approval was obtained before the commencement of the study.

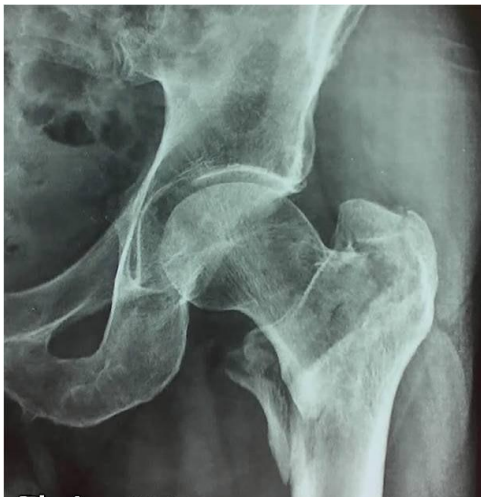

Fig. 1 Pre-operative x ray

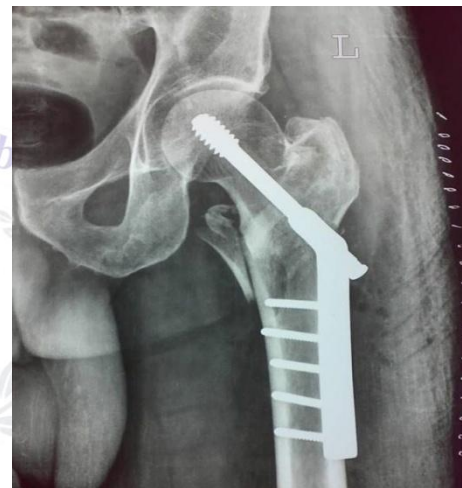


Fig. 2 Immediate Post-operative x ray

Surgical technique-

All the patients were operated using spinal anaesthesia. Fracture reduction and fixation was carried out on a fracture table using the standard reduction techniques. An image intensifier was used to visualize the reduction and also as a guide throughout the procedure for the Richards screw and plate placement. A lateral approach was utilized to expose the hip and a 125°, 130° or 135° angled DHS was used (Fig 2). Non-weight bearing or partial weight bearing walking was begun gradually depending on the fracture configuration and the stability of reduction & fixation. Regular follow-up was done at 3, 6 and 12 months respectively (Fig. 3).

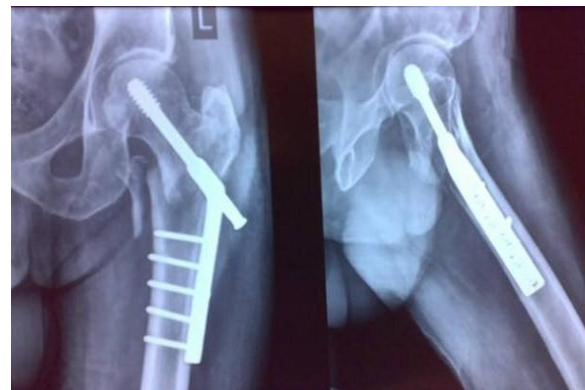

Fig. 3 Follow-up at 6 months

RESULTS

The mean age was 66.2 years (40%). Accidental fall was the most common mechanism of injury in 23 (77%) cases. 19 (64%) cases had right sided involvement. As per the Evan's classification system,

there were 10 (32%) cases of type III, 13 (44%) and 7 (24%) cases of type IV and V respectively encountered in the present study. Average duration of surgery was 51 ± 14.2 mins. Radiological union was observed in 66.7% by 14 weeks, although all united by 18 weeks. By the end of 6 weeks, all the patients were allowed full weight bearing, 11 (36.7%) of them required support in the form of a walking stick. An abductor lurch was observed in 11 (36.7%). A shortening of 2 cms was observed in 8 (27%) cases. There were 2 (7%) cases where dimon hungston type of osteotomy was required. Final outcome was assessed using the Salvati Wilson scoring system. 21 (70%) cases had excellent, 4 (13.33%) cases had good, 3 (10%) cases had fair and 2 (6.67%) cases had poor results respectively.

DISCUSSION

Intertrochanteric fractures are commonly seen occurring in the elderly population with a significant female preponderance. [4-7] The average in the present study was 66.2 years, ranging from 46 to 92 years. Multiple studies conducted have also shown that this fracture is a recurring incident in this age group. [8,9] This study also follows a similar trend with significant numbers affecting the elderly female population. Trivial trauma like a fall in the bathroom, has been cited as the most common cause of these fractures. [10-13]

Wade and Gupta in their studies, observed that the right hip was the most commonly affected side. [14,15] This study also showed significant number of fractures affecting the right hip. Left side fractures were the common side in studies by Kenzor and Cleveland. [11] No cases of bilateral hip involvement were a part of this study.

The majority of the fractures involved in this study were of a type IV configuration according to the Evan's classification. Elderly individuals tend to have a higher degree of comminution due to poor bone quality. There were a few incidences of medialization after weight bearing was initiated.

The average time to radiological union was 14.7 weeks and there were no incidences of nonunion. Ecker et.al. [4] reported fracture union at 15 weeks and in the study by Wolfgang et.al. [16] fracture union was seen at 11 weeks. Both did not report any incidences on nonunion or delayed union. Due to the metaphyseal region of these particular fracture, nonunion is a rare complication that can occur.

Shortening of the involved limb is expected with this system of fracture stabilization. The mechanism of the DHS system with the Richards screw allows the proximal fragment to collapse over the barrel of the DHS attaining a position of maximum stability. A shortening of less than 2cm was seen in the majority of patients in this study.

Full-weight-bearing immediately after the osteosynthesis was possible for 98% of the PFN patients and 81% of the DHS/TBPP patients. The DHS/TBPP osteosynthesis in unstable trochanteric fractures is associated with a higher incidence of complications. Using PFN for unstable fractures of the trochanteric region is highly recommended. [17] This study has not compared this system of fracture fixation but literature has shown many advantages of PFN over DHS with a lower rate of complications for unstable intertrochanteric fractures.

Limitations:

Smaller sample size and less duration of follow-up are the limitations of the present study.

CONCLUSION

The dynamic hip screw with a barrel side plate has the advantage in that it allows controlled collapse of the fracture site. The fixation with dynamic hip screw is rigid even in osteoporotic bone. Though the dynamic hip screw is technically demanding, the implant design and its biomechanical properties have reduced the incidence of joint penetration and implant failure. Postoperatively early mobilization can be initiated at the earliest reducing

morbidity and mortality with a very low rate of complications that are not detrimental to the patient.

REFERENCES

1. Zuckerman, J.D.; Sakales, S.R.; Fabian, D.R.; et al. 'Hip fractures in geriatric patients. Results of an interdisciplinary hospital care program.' Clin Orthop Related Research. 1992;274:213-225.
2. Cummings, S.R.; Kelsey, J.L.; Nevitt, M.C.; et al. "Epidemiology of osteoporosis and osteoporotic fractures". Epidemiol Rev 1985;7:178-208.
3. Zuckerman JD. "Comprehensive care of orthopaedic injuries in the elderly. Baltimore: Urban and Schwarzenberg, 1990.
4. Ecker M.L. et.al.: "The Treatment of Trochanteric Hip Fractures using a Compression Screw". Journal of Bone and Joint Surgery. 1975;57A:23-27.
5. Kulkarni GS: "Treatment of Trochanteric Fractures of the Hip by Modified Richard's Compressing and Collapsing Screw"; Indian Journal of Orthopaedics, 1984;18(1):30-34.
6. Tracy Watson J. et al. "Comparison of the Compression Hip Screw with the Medoff Sliding Plate for Intertrochanteric Fractures"; Clinical Orthopaedics and Related Research. 1998;348:79-86.
7. Schumpelick W and Jantzen PM. A New Principle in the Operative Treatment of Trochanteric Fractures of the Femur. Journal of Bone and Joint Surgery. 1955;37(4): 693-698.
8. Davis TRC, J. L. Sher, A. Horsman, M. Simpson, B. B. Porter, R. G. Checketts: "Mechanical Failure After Internal Fixation"; Journal of Bone and Joint Surgery, 1990;72(1):26 – 31.
9. MJ Parker, CB Maheshwari. The use of Hip scores in assessing the results of treatment of proximal femur fractures. International Orthopaedics. 1997;21(4):262-264.
10. Hornby R, Evans JG Vardon V. Operative or Conservative Treatment for Trochanteric Fractures of the Femur. Journal of Bone and Joint Surgery. 1989;71(4): 619-623.
11. Kenzor JE, McCarthy RE, Lowell JD et al. Hip Fracture Mortality: Relation to Age, Treatment, Pre-operative illness Time of Surgery and Complications. Clinical Orthopaedics and Related Research 1984;186:46-56.
12. Kuderna H, Bohler N and Collon DJ. Treatment of Intertrochanteric and Subtrochanteric fractures of the Hip by the Ender Method. Journal of Bone and Joint Surgery 1976;58(5):604-611.
13. Ganz R, Thomas RJ and Hammerle CP. Trochanteric Fractures 1999 of the Femur: Treatment and Results. Clinical Orthopaedics and Related Research 1979;138:30-40.
14. Gupta RC. Conservative Treatment of Intertrochanteric Fractures of the Femur. Indian Journal of Orthopaedics. 1974; 36(6): 229.
15. Wade PA. Management of Intertrochanteric Fractures of the Femur; Am J Surgery 1959;97:634-643.
16. Wolfgang GL, Bryant MH, O'Neill JP.: "Treatment of Intertrochanteric Fracture of the Femur Using sliding Screw Plate Fixation"; Clin Orthop Relat Res. 1982;163: 148-58.
17. Klinger HM, Baums MH, Eckert M, Neugebauer R. [A comparative study of unstable per- and intertrochanteric femoral fractures treated with dynamic hip screw (DHS) and trochanteric butt-press plate vs. proximal femoral nail (PFN)]. Zentralbl Chir. 2005;130 (4):301-6.

How to cite this article: Pradeep AP, Faisal Q, Gudda NL et al. Treatment of unstable intertrochanteric fractures using dynamic hip screws - a prospective study. International Journal of Research and Review. 2017; 4(2):19-22.
