

Case Report

## Bilateral Rectus Sternalis Muscle- Case Report

Amrutha K V<sup>\*</sup>, Joseph Abraham<sup>\*</sup>, Admasu Arsicha<sup>#</sup>, Teshome Belachew<sup>\$</sup>,  
Assefa Hamato<sup>@</sup>

Preclinical Coordinator, Yirgalem Hospital Medical College<sup>@</sup>

Academic Affairs Vice Dean, Yirgalem Hospital Medical College<sup>\$</sup>

Dean, Yirgalem Hospital Medical College<sup>#</sup>

Assistant Professor, Anatomy Department, Yirgalem Hospital Medical College<sup>\*</sup>, Ethiopia

Corresponding Author: Dr. Joseph Abraham

### ABSTRACT

Pectoralis major muscle is a well known muscle of body. Sometimes we may find a linear muscle superficial to it, which may be considered as supernumerary, called rectus sternalis. Here we are going to explain rectus sternalis muscle, which we found on both sides. During management of pectoral region, radiologist and surgeons should have the knowledge of this muscle.

**Key words:** Pectoralis major; medial and lateral Pectoral nerves; rectus sternalis muscle

### INTRODUCTION

In 1604, Cabrolus initially explained sternalis followed by Dupuy in 1726. [1] This muscle is also called as presternalis, musculus sternalis, sternalis brutorum, rectus sternalis etc. [2] This muscle lies on either side of sternum, from the level of costal region to jugular notch, superficial to pectoralis major. [3,4]

It is most commonly unilateral than bilateral and the frequency varies among different ethnic groups. However, there is a great variation in height, width, and thickness of this muscle. Its presence ranges from a few short fibers to a well-formed muscle. [5] The incidence is more in Chinese 23.5% and lowest in Taiwanese 1%. The incidence of this muscle within Asians is 11.5%. [5-8] Still it is controversial regarding nerve supply of rectus sternalis muscle. It might have originated from pectoralis major, sternocleidomastoid, or from panniculus carnosus. [8] Let's see an interesting case here.

### CASE REPORT

We found bilateral presternalis muscle in a male cadaver, of about 50 years old, while performing routine dissection by MD students(2<sup>nd</sup> year) in Yirgalem Medical College and Hospital. It was located on pectoral region in anterior thoracic wall and related to skin, superficial fascia anteriorly and pectoral fascia, sternocostal fibers of pectoralis major muscle inferiorly. On both sides rectus sternalis was seen originating from the aponeurosis of the external oblique muscle, ran upwards along the lateral borders of sternum. At the angle of Louis they became tendinous and joined together forming an inverted U shaped aponeurosis. Further the aponeurosis on both side extended to medial end of clavicle and became continuous with sternocleidomastoid muscle ([figure 1](#)). It was innervated by intercostal nerves.

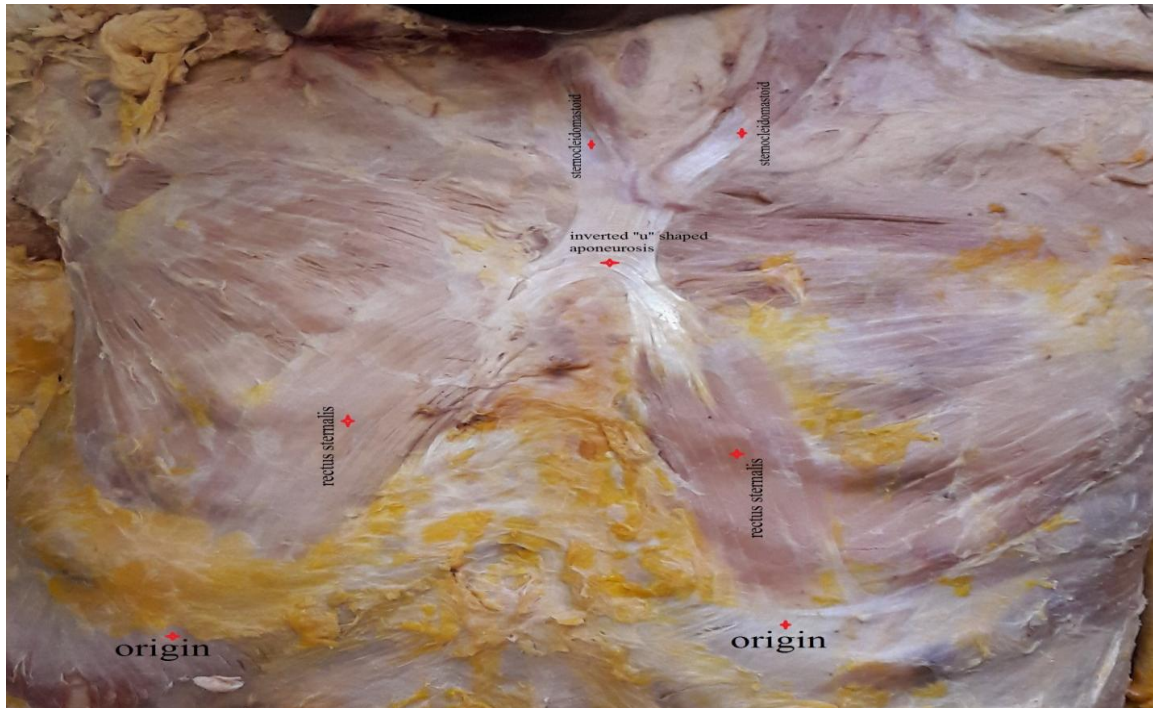


Figure 1: bilateral rectus sternalis muscle seen originating from external oblique aponeurosis, forming an inverted U shaped aponeurosis at angle of Louis, and continuing with sternocleidomastoid

## DISCUSSION

Embryologically rectus sternalis arises from ventral longitudinal column of muscle; arising from ventral tip of hypomeres.<sup>[9]</sup> According to literature bilateral rectus sterni muscle if derived from rectus abdomen is muscle was supplied by intercostals nerves as both were derived from ventral longitudinal paramedian muscular sheet represented in human being by the hyoid muscles in the neck, the rectus abdominis muscle in the abdomen, and occasionally the rectus sterni muscle in the thorax.<sup>[7,10-13]</sup>

Some anatomists also suggest that the sternalis muscle develops from unusual migration of pectoral mass. Hung believed that this mass splits into a superficial (pectoralis major) and deep layer (subclavius, pectoralis minor, pectoralis abdominalis [abdominal part of pectoralis minor]) which eventually migrates caudally to the costal region where it splits into two bundles: the clavicular portion and the sternocostal portion. The sternocostal portion differentiates into the sternocostal part of pectoralis major and pectoralis minor. An abnormal migration or cleavage

of the pectoral mass may lead to the formation of sternalis muscle.<sup>[14]</sup>

While the attachment sites and presentation of sternalis muscle (SM) are generally agreed upon, the innervations and embryological origin of the muscle remain topics of debate. Nerve supply to SM is commonly reported as coming from the pectoral nerves (medial or lateral pectoral)<sup>[15-20,9]</sup> or anterior cutaneous branches of the intercostal nerves.<sup>[21-28,7,11]</sup> According to Barlow, a literature review of 146 SM cases, reported by 17 authors, found that SM is supplied by the pectoral nerves in 68.5% of cases, intercostal nerves in 26.7%, and a combination of the two in 4.8%.<sup>[13]</sup> In a literature review spanning 191 SM cases reported by 34 authors, O'Neill & Folan-Curran found SM to be supplied by pectoral nerves in 55% of cases, by intercostals in 43%, and a combination of the two in 2% of cases.<sup>[24]</sup> Kida et al. have suggested that the delicate and fine nature of the branches of the pectoral and intercostal nerves make them difficult to dissect due to their susceptibility to being damaged, misidentified as connective tissue, or overlooked. These factors lead to difficulty

in tracing their potential innervations to SM. [20]

The unilateral sternalis muscle has been reported to be present in 4.5% of subjects, while the bilateral manifestation is found in less than 1.7% Incidence of the sternalis muscle varies widely between nationalities, 4% to 7% in white population, 8.4% in black population, 11.5% in Asian population, and 9.3% in Turkish population as referred by Schaeffer. [28,29]

The awareness of the sternalis muscle is wide spread amongst anatomists, however it is lacking in physicians, surgeons and radiologists. The sternalis can mimic a tumour on mammography, which results in misdiagnosis and unnecessary invasive investigations or procedures. It may also be mistaken for a recurrence of a tumor following surgery on follow-up. Surgeons and radiologists should be aware of this rare entity during breast surgery so that if present, it can be identified and the appropriate dissection plane recognized. [1]

## CONCLUSION

The aim of this paper is to raise awareness of sternalis muscle (SM) amongst health care providers and educators of medicine. It becomes essential to look for chest area in a patient, when the same presents spina bifida occulta, as SM may be seen along with spinal anomalies. Clarification of the development of SM in relation to the axial skeleton is necessary to resolve the uncertainty around its nerve supply.

## ACKNOWLEDGEMENTS

We would like to thank 2nd year MD students for all their help and support during the dissection and preparation of the material.

## REFERENCES

1. Thute P, Harsha B, Ujwal G, Eti S, Sunita B, Manjiri C et al. The Bilateral Sternalis: an Uncommon Anatomical Variant. *Journal of Clinical and Diagnostic Research* 2012; 6(4):1-3.
2. Shankar VV, Rajan R, Nanjundaiah K, Chowdapurkar S. Rectus sternalis muscle- a rare variant. *National Journal of Clinical Anatomy* 2013;2(1):41-3.
3. Singla RK, Sachdeva K. Bilateral Musculus Sternalis: A Case Report. *Journal of Clinical and Diagnostic Research* 2012;6(3):465-68.
4. Raikos A, Paraskevas GK, tzika M, faustmann P, Triaridis S, Kordali P et al. Sternalis muscle: an underestimated anterior chest wall anatomical variant. *Journal of cardiothoracic surgery* 2011;6(1):73-6
5. Athanasios R, George KP, Maria T, Pedro F, Stefanos T, Panagiota K et al. Sternalis muscle: an underestimated anterior chest wall anatomical variant. *Journal of Cardiothoracic Surgery*. 2003; 6(1): 73
6. Silveira D, Sousa LM, Siqueira SL, Oliveira BVM, Silva AT, Costa JP et al. Sternalis muscle: an anatomic variation of the anterior chest wall. *Journal of Morphological Sciences*. 2012; 29(2): 76-78
7. Motabagani MA, Sonalla A, Abdel-Meguid E, Bakheit MA. Morphological study of the uncommon rectus sterni muscle in German cadavers. *East African Medical Journal*. 2004;81(3):130-3.
8. Hitendra K, Gayathri R, Mahesh S, Mangala K, Bidya R. Bilateral sternalis with unusual left sided presentation. A clinical perspective. *Yonsei medical journal*. 2003; 44 (4): 719-722.
9. Kumar H, Rath G, Sharma M, Kohli M, Rani B. Bilateral sternalis with unusual left sided presentation: A clinical perspective. *Yonsei Med J*. 2003;44(4):719-22. 4
10. Shah AC. The Sternalis muscle. *Indian J Med Sci*. 1968; 22:46-7.
11. Jeleu L, Georgiev G, Surchev L. The sternalis muscle in the Bulgarian population: Classification of sternales. *J Anat*. 2001;199:359-63.
12. Yap SE. Musculus sternalis in Filipinos. *Anat Rec* 1021;21:353-71.
13. Barlow, R. N. The sternalis muscle in American whites and Negroes. *Anat. Rec.*, 61(4):413-26, 1935.
14. Hung LY, Lucaciu OC. Viewpoint: The Embryological Development of Sternalis Muscle and Implications for Trigger Point Pain. *UTMJ* 2012;90(2):24-7
15. Wallace, D. Nerve Supply of Musculus Sternalis. *J. Anat. Physiol.*, 21(1):153-4, 1886.
16. Lamont, J. C. Notes on the Nervous Supply of the Musculus Sternalis. *J. Anat. Physiol.*, 21(3):514-5, 1887

17. Cunningham, D. J. The musculus sternalis. *J. Anat. Physiol.*, 22(3):390.1-407, 1888.
18. Patten, C. J. Right Sternalis Muscle, Narrow and Spindle-shaped. *J. Anat.*, 68(3):426, 1934.
19. Harper, W. F. The Sternalis Muscle in the Anencephalous Foetus. *J. Anat.*, 70(2):317-20, 1936
20. Kida, M. Y.; Izumi, A. & Tanaka, S. Sternalis muscle: topic for debate. *Clin. Anat.*, 13(2):138-40, 2000.
21. Shepherd, F. J. The Musculus Sternalis and its occurrence in (Human) Anencephalous Monsters. *J. Anat. Physiol.*, 19(3):310.2-319, 1885.
22. Shen, C. L.; Chien, C. H. & Lee, S. H. A Taiwanese with a pair of sternalis muscles. *Kaibogaku Zasshi*, 67(5):652-4, 1992.
23. Jeng, H. & Su, S. J. The sternalis muscle: an uncommon anatomical variant among Taiwanese. *J. Anat.*, 193(2):287-8, 1998.
24. O'Neill, M. N. & Folan-Curran, J. Case report: bilateral sternalis muscles with a bilateral pectoralis major anomaly. *J. Anat.*, 193(2):289-92, 1998.
25. Saeed, M.; Murshid, K. R.; Rufai, A. A.; Elsayed, S. E. & Sadiq, M. S. Sternalis. An anatomic variant of chest wall musculature. *Saudi Med. J.*, 23(10):1214-21, 2002.
26. Arráez-Aybar, L. A.; Sobrado-Perez, J. & Merida-Velasco, J. R. Left musculus sternalis. *Clin. Anat.*, 16(4):350-4, 2003.
27. Gupta, M. & Harjeet. Bilateral sternalis in relation to body of sternum. *Nepal Med. Coll. J.*, 6(1):62-3, 2004.
28. Sarikçioğlu, L.; Demirel, B. M.; Oguz, N. & Uçar, Y. Three sternalis muscles associated with abnormal attachments of the pectoralis major muscle. *Anatomy*, 2:67-71, 2008.
29. Schaeffer JP. *Morris' Human Anatomy*. 10 edition. Philadelphia: The Blackiston Company. 1942:437.

How to cite this article: Amrutha KV, Abraham J, Arsicha A et al. Bilateral rectus sternalis muscle-case report. *International Journal of Research and Review*. 2018; 5(5):7-9.

\*\*\*\*\*