

Tall and Tilted Pin Hole Immediately Loaded Implants (TTPHIL) Technique for Maxillary Arch Rehabilitation

Dr. P. Venkat Ratna Nag¹, Dr. P. Sarika², Dr. Ruheena Khan³,
Dr. Tejashree Bhagwatkar⁴

¹Reader, Department of Prosthodontics, S.B. Patil Dental College and Hospital, Bidar
& Director, Institute for Dental Implantology Hyderabad

²Reader, Department of Pedodontics and Preventive Dentistry, S.B. Patil Dental College, Bidar

³Oral Medicine and Radiologist, Institute for Dental Implantology, Hyderabad

⁴Oral Pathologist, Institute for Dental Implantology, Hyderabad

Corresponding Author: Dr. P. Venkat Ratna Nag

ABSTRACT

Although dental implantology has evolved over the years with different techniques such as conventional and basal implants through immediate and delayed loading, there exists still a dilemma among modern clinicians regarding the concept of immediate implantation along with prosthetic loading. The aim of this article is to provide an overview of newer technique called Tall and Tilted Pin Hole Immediately Loaded implants (TTPHIL). This article describes a case report of immediate loading with bicortical longer implant engaging nasal bone.

Key words- Dental Implant, Immediate implantation, TTPHIL technique, Basal implant, Immediate loading, Bicortical implant

INTRODUCTION

As skin is considered as the best dressing for the wound, tooth is the best stimulant for the jaw, in their absence, definitely a dental implant. [1]

Complete tooth loss can be the result of many conditions like severe periodontitis, trauma, dental caries and intentional extraction, post-surgical or after radiotherapy in oral carcinoma, etc. The affordable option, which has been advised by the most of the dentists, is the complete denture. But, the complete dentures are not very much comfortable for most the patients because of inadequate retention and stability, soft tissue erosions, gagging, improper speech etc. [1]

In recent times, dental implant supported prosthesis (implant over dentures)

has offered many advantages such as improved retention and support, reduced size prosthesis, better speech, and enhanced mastication ability when compared to the conventional methods. [2,3]

Full mouth implantation is a conventional technique which works on the placement of implants and keeps them undisturbed for subgingival healing till osseointegration of bone takes place. These implants are uncovered only after the subgingival healing which takes for approximately 3 to 6 months basically depends on various factors like bone density, occlusal load, implant dimensions etc. and restored in function once the soft tissue get heal in next 3 to 4 weeks. [4,5]

The full mouth rehabilitation is difficult in many cases because the

edentulous patients usually do not have adequate bone dimensions for the placement of implants. [6] Conventional method for full mouth implant supported fixed prosthesis requires placement of multiple number of implants, bone grafting/augmentation procedures, increased treatment duration and multiple number of surgical steps, not always comfortable and affordable. [7]

The concept of tilted implant demonstrates that the back implants are slanted distally to place implant head at the second premolar or first molar region. It is considered as a graft less implant placement procedure for restoring the edentulous jaws by tilting posterior implants so that maximum amount of bone can get utilized and stabilized them into highest possible bone density and avoiding sinus lift procedures. [7,8]

Advancement in implant dentistry allowed a shift from the early paradigms established by the work of Branemark and coworkers. While initial healing of 6 months in the maxilla and 3 months in the mandible was recommended. [9]

This case report aims to explain the graft less approach for full arch immediate rehabilitation by placing six implants in maxillary arch by smartly tilting all the implants to avoid vital structures, such as maxillary sinus and stabilizing into the high density bone taking bicortical anchorage.

CONCEPT OF TTPHILTECHNIQUE

The concept of tilted implants was described by Paulo Malo, Lisbon, Portugal in his state of art All-on-4™ Concept. In this technique, the back implants are slanted distally to place the implant head at the second premolar or first molar position which helps to place longer implants, stabilizing their apices into the anterior higher bicortical bone, and reducing the distal cantilever of the prosthesis.

In this technique four implants are used two straight implants are placed close to the midline and other two implants are placed anterior to the maxillary sinus (in maxilla) or mental foramen (in mandible)

which are slanted distally to reach the second premolar or first molar position. A 10 to 12 unit screw-retained metal to acrylic (hybrid) splinted prosthesis is placed over the implants. [10] But in few patients 10 to 12 unit prosthesis is inadequate due to reduction in mastication and cantilever is more. In such patients, two additional implants are placed posterior to the sinus into the tuberopterygoid bone in the maxilla to support 14 to 16 unit prosthesis. [8] This will help facilitate a proper support for an acrylic prosthesis which can be immediately fixed over the implants to restore the esthetics and functions within few hours after the implant insertion. [11]

TTPHIL™ concept is the newer technique which not only overcomes limitations of axial implants but also disadvantages of All-on-4 concept. Tall (18mm-25mm), Tilted (TT) implants (30°-45°) are placed. Tall implants considered good for osseointegration as it provide more surface area and also engaged to the cortical bone i.e. bicortical anchorage. The implants are placed in Pinhole (PH) manner i.e. flapless. All implants are immediately loaded (IL) within 48 hours after extraction. [12,13]

CASE REPORT

Diagnosis and treatment planning

A 50 year old male patient reported with a chief complaint of mobility in the back teeth region and food lodgment, pain in his anterior bridge and wants fixed teeth immediately and permanent solution for his full maxillary arch (fig. 1). A complete case history was recorded followed by thorough intraoral examination. On intra oral examination, maxillary anterior bridge and maxillary posterior teeth were mobile. Computed tomography (CT) and Orthopantomogram (OPG) (fig. 2) demonstrated very little bone was present in the maxillary sinus region. CT scans were carefully studied for the thickness and height of bone in the tuberosity region. The mouth opening was assessed and found to be adequate for placing implants in the

tuberosity region. Considering the amount of residual bone and request of immediate teeth, it was decided that placing implants using TTPHIL technique was the best alternative. Routine blood investigations were done and fitness obtained for surgical procedure.

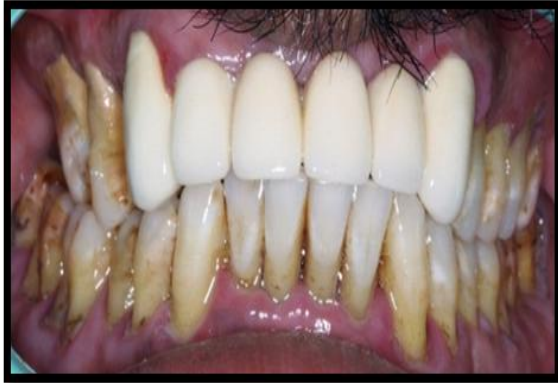

Figure 1: Clinically, maxillary falling fixed anterior bridge and mobile posterior teeth

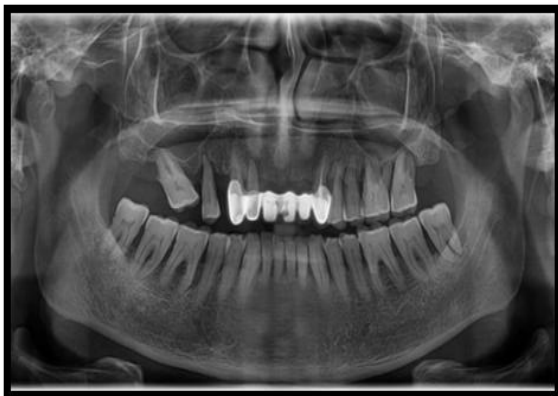

Figure 2: OPG showing bone loss in the maxillary posterior region

Surgical protocol

Medication

Patient consent was taken prior to surgical procedure. Surgical protocol emphasized complete asepsis and infection control. Amoxicillin 1 g for 1 h before surgery then 500 mg for 3 times daily for the next 3 days. Before the surgical procedure, the patient was instructed to rinse with 0.2% chlorhexidine gluconate for 1 min.

Anaesthesia

All implants are placed under local anaesthesia. 2% lignocaine hydrochloride with adrenaline (1:200000) was used.

Implantation surgery

Extractions of the teeth were done atraumatic with the luxators and forceps, deep curettage and socket debridement was done with the ultrasonic scaler. Lancet drill (1.2mm up to 6 mm) on pterygoid region acts as guidance point for implant placement, proper mesio distal and bucco lingual tilt. It help check whether it is perforating maxillary sinus (fig.3). Therefore, RVG was taken. Pilot drills were used 2.5 mm drill for 3.25/3.5 implant, 2.75mm drill for 3.75 mm implant under preparation of the sound bone. Bioline I-spiral implant 3.75x20mm diameter and length of implants were planned and two placed in the canine region, two implants in the 2nd premolar region and two implants in the pterygoid region (fig.4). Multi unit abutments is placed for canine- 30 degrees, 2nd premolar- 45 degree, while in 2nd molar pterygoid region 45 degree. Multiunit Implant parallelism was obtained (fig.5). An Injection NSAIDs intramuscular was given to the patient just after surgery to reduce postoperative pain and swelling. OPG showed tall and tilted implants after placement (fig.6). Patient was recalled after one week. Temporary abutment was placed on these multi units abutments and provisional bridge was fixed for 3 months and wait for healing. Occlusion was checked properly with no excursive contacts.

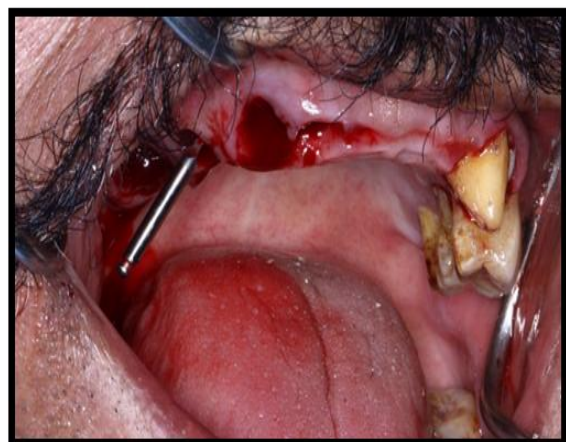


Figure 3: Atraumatic extraction and Lancet drill (1.2mm, 500 rpm) is used

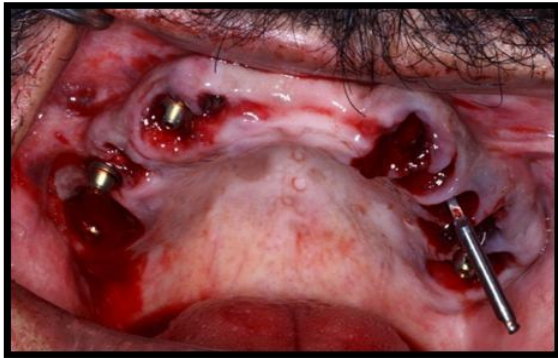

Figure 4: Atraumatic extraction and Pilot drill (1.2mm, 500 rpm) is used and immediate placement of six implants

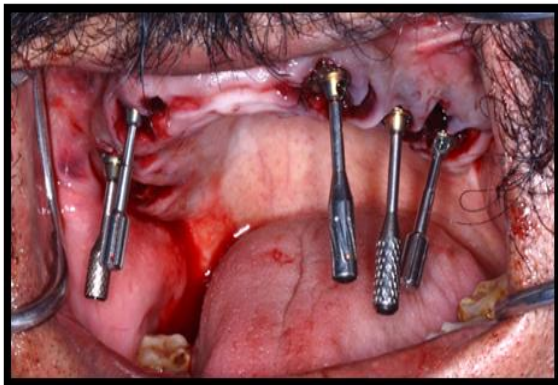


Figure 5: Implant Parallelism was obtained

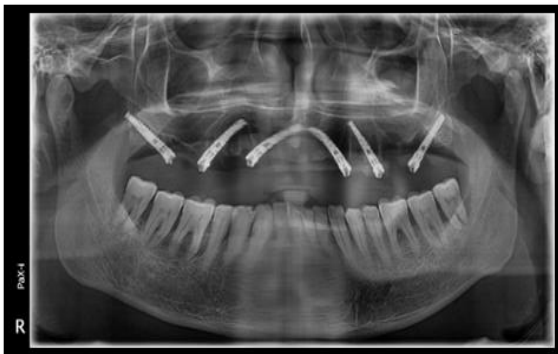

Figure 6: OPG showing tall and tilted implants after placement

Prosthetic replacement- Temporary

After surgical intervention, temporary abutments were placed to the patient multiunits which were made parallel to each other to compensate the implant angulation on the same day of surgery. Alginate impressions were taken and bite was recorded in centric relation. Immediate provisionalization was done with self cure acrylic and cemented it with provisional cement (IRM). Occlusion was checked and seen to it that bilateral contact and group function was gained without any excursive contacts

Prosthetic reconstruction- Permanent

After 3 months patient visited to us and the temporary were removed and shows with good healing (fig. 7). Plastic tray was selected for full maxillary arch impression for which distance minimum of 5-10 mm between the tray and the impression (fig. 8). Two step open tray impression were taken with putty and light body (fig. 9). Multi-unit implant analogues were placed and tighten (fig. 10) after which a jaw relation was recorded (fig. 11) and sent for laboratory for CAD CAM designing screw retained fixed prosthesis. Direct Metal Laser Sintered Cobalt Chromium Copings were printed. After two days the patient was rehabilitated with immediately placed and loaded all ceramic screw retained fixed prosthesis (fig. 12). Implant occlusion was group function (fig. 13). Post operative OPG was taken (fig. 14). Patient was happy and satisfied with the prostheses (fig.15). A follow-up of implant survival was done up to 1 year. OPG taken after 3 year follow up (fig.16).

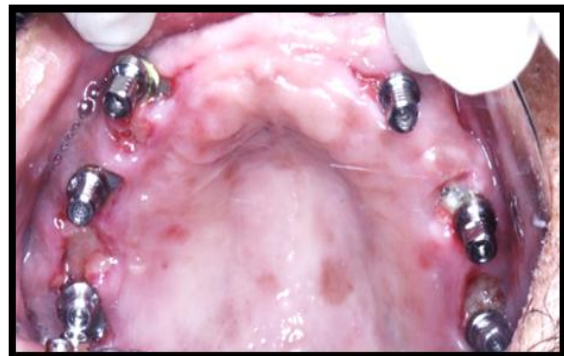

Figure 7: Six implants in the maxilla with good tissue healing

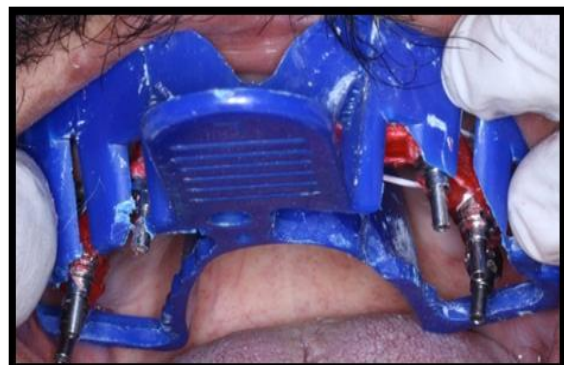


Figure 8: Open plastic tray is selected and modified for full maxillary arch impression

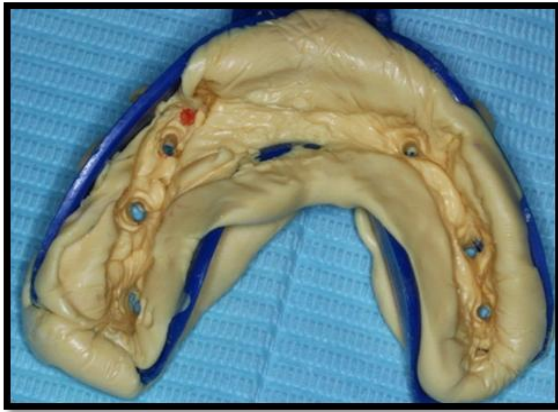

Figure 9: Putty impression with cellophane sheet

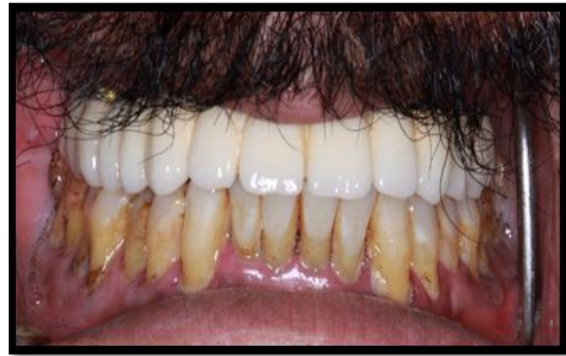

Figure 13: Canine guided occlusion given with anterior guidance

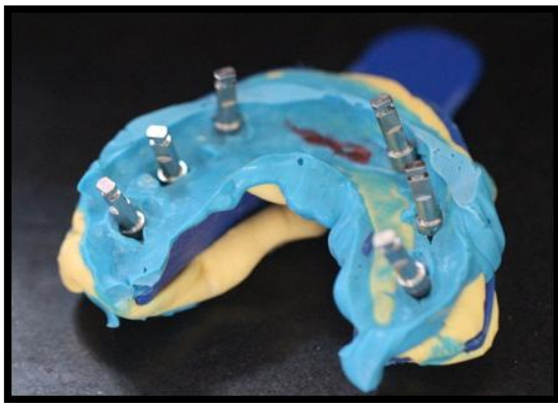


Figure 10: Multi-units implant analogues were placed and tighten them

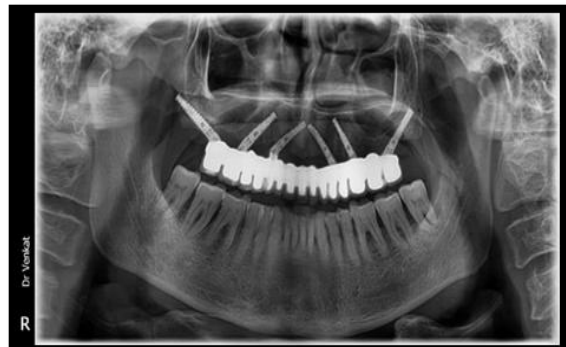

Figure 14: Postoperative OPG immediately after fixed implant prostheses

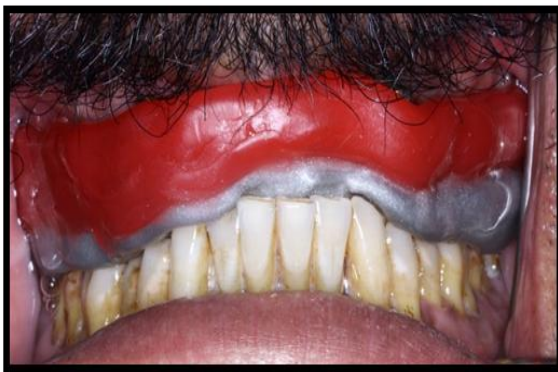

Figure 11: Bite registration done



Figure 15: Happy patient with maxillary fullarch fixed prostheses

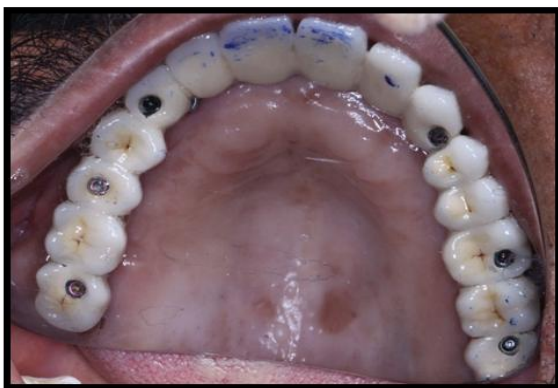

Figure 12: Screw retained fixed implant prostheses

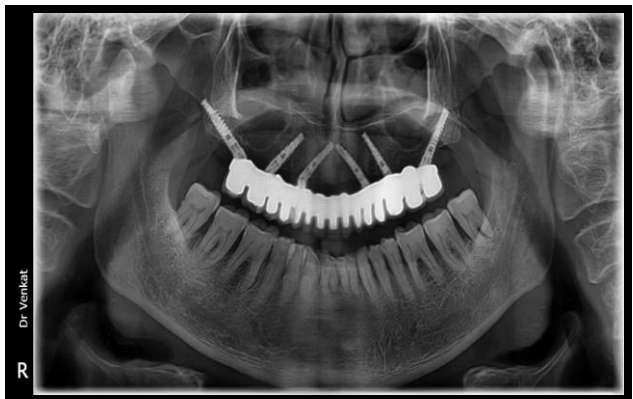

Figure 16: Post operative OPG after 3 years

DISCUSSION

To achieve bone-to-implant contact (i.e. osseointegration), oral implants placed mostly in two-stage surgical procedure used to remain unloaded for a healing period of 3-6 months. Now in literature, many studies were advocated and questioned the necessity for a long implant healing period. [14]

The current case report also supports the concepts that the implants can be loaded early or immediately. [15] There are many factors like bi-corticalization, one time abutment concept, bone condensation, height stability factors, flap implant placement and screw retained prostheses allows us to do immediately loading. Several long-term studies on single-tooth replacement have shown excellent results over a 5-year period. [16] Full mouth rehabilitation also proven high success. [17,18]

In literature Tall and Tilted Pin Hole Immediately Loaded implants (TTPHIL) technique is innovative technique and few cases were reported on it and our cases proven higher success rates can be indicated in immediate restoration of resorbed maxilla and mandible with minimal surgical procedure. Tall will increase bone to implant contact. Bicortical anchorage transfers the forces to cortical bone which is highly mineralized and least resistance to bone resorption. Tilted to bypass the sinus and luting structures. Moreover increase the length by tilting. The bone to implant contact which is improved for osseointegration. By using Pin hole periosteal blood vessels are intact as no flap was raised. Immediate multiunit abutment will prevent and cooperate angulation of implant and utilizes the concept of muointegration. One time abutment concept thereby placing till gum level. [12,13]

CONCLUSION

Appropriate diagnosis and treatment planning is key role for full mouth rehabilitation. Implant therapy is most reliable treatment option to replace missing

teeth. The TTPHIL technique for completely edentulous patients has proven to be clinically effective technique, patient pleasing and applicable in various clinical situations where otherwise more invasive, few complicated and expensive bone augmentation procedures, sinus lifting would have been indicated. This concept can be adopted by the dentists to deliver a short treatment procedure and extraction followed by implants insertion surgery on same day.

Conflict of interest- No

REFERENCES

1. Dwivedi H, Jain R. Immediate loading with single-piece implant following extraction. *Indian J Dent Sci* 2017;9:S39-43.
2. Thomason JM, Feine J, Exley C. Mandibular two implant-supported overdentures as the first choice standard of care for edentulous patients. *Br Dent J* 2009 Aug 22;207(4):185-186.
3. Singh AV, Singh S, Rojo AV. Quality life for elderly edentulous patients with implant over dentures, implantology section. *Dental Practice* 2013 May-June;11(6):22-25.
4. Zitzmann NU et al. Treatment outcomes of fixed or removable implant - supported prostheses in the edentulous maxilla Part I: patients assessments. *J Prosthe Dent* 2000, 83:424-433.
5. JI Stoeinga PJW et al. Reconstruction of the severely (class VI) maxilla. A two-step procedure. *Int J Oral MaxillofacSurg* 1994; 23:219-225.
6. Singh AV, Singh S. Keys to success for implant placement in posterior maxilla, implantology section, *Dental Practice* 2013 March- April; 11(5):20-24.
7. Singh AV. Implants into pterygoid bone. *Clinical Implantology @ 2013 Elsevier*, ISBN 978-81-312-3324-5. p. 593-601)
8. Singh AV, Singh S. Tilted Implant concept for full mouth immediate loading restoration. *Int J Oral ImplantolClin Res* 2014;5(1):12-23.
9. Clark Stanford, DDS, PhD., All on four-where are we now. *The International Journal of Oral & Maxillofacial Implants*. 29(2) (2014).
10. Maló P, Rangert B, Nobre M. 'All-on-Four' immediate function concept with Brånemark

- System implants for completely edentulous mandibles: a retrospective clinical study. Clin Implant Dent Relat Res 2003;5:S2-S9.
11. Maló P, Rangert B, Nobre M. 'All-on-4' immediate-function concept with Brånemark System implants for completely edentulous maxilla: a 1-year retrospective clinical study. Clin Implant Dent Relat Res 2005;7:S88-S94
 12. VenkatRatna Nag. P et al. TTPHIL-ALL TILT TM Concept-An Innovative Technique in Immediate Functional Loading Implant Placement in Maxilla. Sch. J. Dent. Sci., 4 (9); 2017, pp-397-399
 13. P VenkatRatna Nag. Immediate Implant Placement and Loading With Tall And Tilted Pinhole Immediate Loading (Ttphil) Technique. Guident Sep 2017:26-27
 14. Do GiaKhang Hong and Ji-hyeon Oh. Recent advances in dental implants. Maxillofacial Plastic and Reconstructive Surgery (2017) 39:33
 15. Krikor D, Krikor S. Immediate Loading of Dental Implants: Overview and Rationale. CDA Journal 2005;33(4):337-341
 16. Becker W, Becker BE. Replacement of maxillary and mandibular molars with single endosseous implant restorations: A retrospective study. J Prosthet Dent 1995; 74:51-5.
 17. Sompop B, Debra SS et al. Full Mouth Rehabilitation with Implant-Supported Protheses for Severe Periodontitis: A Case Report 2010. *The Open Dentistry Journal*; 4:165-171
 18. Esposito MA, Koukoulopoulou A, Coulthard P, WorthingtonHV. Interventions for replacing missing teeth: dental implants in fresh extraction sockets (immediate, immediate-delayed and delayed implants). Cochrane Database Syst Rev 2006; 4: CD00596.

How to cite this article: Nag PVR, Sarika P, Khan R et al. Tall and tilted pin hole immediately loaded implants (TTPHIL) technique for maxillary arch rehabilitation. International Journal of Research and Review. 2018; 5(6):104-110.
