

Original Research Article

Comparison between Tubularised Incised Plate Urethroplasty with Preputial Flap Urethroplasty in Anterior and Mid Penile Hypospadias

Dr Rakesh Kumar Tripathi¹, Dr Shyam Sundar Sahu², Dr Saurav Singh³,
Dr Prateek⁴, Dr Pinaki Ranjan Debnath⁵

¹Associate Professor, Paediatric Surgery, GSV Medical College, Kanpur.

²Senior Resident, Paediatric Surgery, PGIMER & Dr RML Hospital, New Delhi.

^{3,4}Junior Resident, Surgery, GSV Medical College, Kanpur.

⁵Associate Professor, Paediatric Surgery, PGIMER & Dr RML Hospital, New Delhi.

Corresponding Author: Dr Pinaki Ranjan Debnath

ABSTRACT

Introduction - Hypospadias is a common congenital anomaly of the male gender. It is classified into distal or anterior, middle and proximal or posterior hypospadias which are further sub-divided into different types on the basis of the location of the meatus.

Aims - To compare between tubularised incised plate and preputial flap onlayurethroplasty for single stage urethroplasty for anterior and mid penile hypospadias without or minimal chordee.

Materials And Methods - 75 boys were selected from patients presenting to the LLR Hospital, having hypospadias anomaly. All had comparable anterior and mid-penile deformities with no apparent or minimal chordee.

Result - Both technique result in acceptable anterior position of neomeatus and had comparable complication rates. Onlay flap repair have more fistula rate and dehiscence rate. TIP repair has more meatal stenosis rate

Conclusion- We prefer TIP repair as being technically easier with simple complications, superior cosmetic outcome and satisfying vertical slit like meatus.

Key words: Hypospadias, tubularised incised plate urethroplasty, preputial flap, urethroplasty

INTRODUCTION

Hypospadias is a common congenital anomaly of the male gender in which external meatus is located abnormally on the ventral surface of the shaft of the penis or even perineum. [1,2] It is classified into distal or anterior, middle and proximal or posterior hypospadias which are further sub-divided into different types on the basis of the location of the meatus. [1,3]

Etiology

The underlying cause for nonsyndromic hypospadias in most

individual cases is unknown. Based on knowledge of normal penis formation and the presumption that hypospadias represents arrested development, several causes may exist.

Genetic Factors

Familial aggregation is found in 4% to 10% of hypospadias cases, including first-, second-, and third-degree relatives (Calzolari et al, 1986; Harris and Beaty, 1993; Fredell et al, 2002; Schnack et al, 2008). A recent national registration-based study from Denmark (Schnack et al, 2008) included 1.2 million males with 5380

hypospadias cases, reporting hypospadias equally transmitted through maternal and paternal sides of the family, with recurrence risk ratios similar for twin brothers, brothers, and sons. Difficulties in establishing recurrence risks include Despite these limitations, a consistent conclusion is that familial aggregation is best explained by genetic factors rather than environmental exposure (Calzolari et al, 1986; Stoll et al, 1990; Schnack et al, 2008).

Associated Anomalies

- Cryptorchidism
- Prostatic Utricle
- Disorders of Sex Development
- Malformation Syndromes
- Upper Urinary Tract Anomalies.

Pre-Operative Investigation

- Radiological studies: To rule out upper urinary track anomalies.
- Karyotyping: To rule out syndromic and non-syndromic hypospadias.
- Routine Blood Investigations:
 - CBC
 - RBS
 - Electrolytes
 - LFT
 - KFT

Aim and Objective

To compare between tubularised incised plate and preputial flap onlayurethroplasty for single stage urethroplasty for anterior and mid penile hypospadias without or minimal chordee.

MATERIALS AND METHODS

Study Design: Prospective interventional study.

Selection of cases: Seventy five boys were selected from patients presenting to the LLR Hospital, having hypospadias anomaly. All had comparable anterior and mid-penile deformities with no apparent or minimal chordee.

Inclusion Criteria:

Anterior and mid-penile hypospadias without or minimal chordee.

heterogeneity in the severity of hypospadias in probands, reliance on family histories introducing recall bias, and inclusion of patients with unrecognized syndromal hypospadias (Harris and Beaty, 1993; Schnack et al, 2008).

Exclusion Criteria:

Presence of Chordee

Any previous hypospadias surgery

Methods:

Artificial erection test was done intraoperatively to rule out cases with severe chordee. 3 Patients were 24 months or more at the time of operation. Parents were informed of the study's aim, methods and written consents were obtained.

Cases were randomly assigned to undergo either a TIP urethroplasty or an onlay preputial island flap repair. Operative details for each patient were recorded. TIP procedure was done according the technique described by Snodgrass. Cases assigned to the second group underwent the onlay preputial island flap repair described by Duckett. In TIP patients, urinary diversion was carried out using an 8 Fr silicone stent for 5-7 days post operatively and in onlay preputial flap patients stent carried out on 14 post operative day. All patients were done by the same surgical team and were followed up for a minimum period of one year postoperatively; during which three groups of parameters were compared.

OBSERVATION

Cosmetic Results

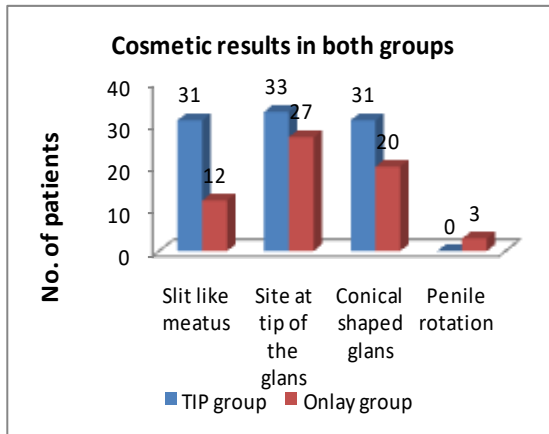
Seventy five patients were studied and completed the minimum 12 months follow up period. Three groups of variables were recorded and compared. Natural looking vertical slit like meatus was achieved in 78% cases in the TIP group (31/40), versus 34% in the Onlay technique (12/35) and the rest of cases had rounded shaped meatus. The difference was statistically significant in favor of TIP group. The site of the meatus was at the tip of the glans in 83% of cases in the TIP group and 77% in the Onlay groups with no statistical difference. Conical shaped glans

has been achieved in 78% in the TIP and 57% in the Onlay group and this was statistically insignificant. Penile rotation was encountered in the Onlay group (3

cases), this rotation was less than 300 and did not need surgical correction. No cases were recorded in the TIP group (Table 1).

Table 1: Cosmetic results in both groups

Cosmetic outcome	TIP group (n=40) No (%)	Onlay group (n=35) No (%)	P value	Significance
Slit like meatus	31(78%)	12 (34%)	0.002	Highly significant
Site at tip of the glans	33 (83%)	27(77%)	0.578	Non significant
Conical shaped glans	31(78%)	20 (57%)	0.829	Non significant
Penile rotation	00(0%)	3(9%)	0.096	Non Significant



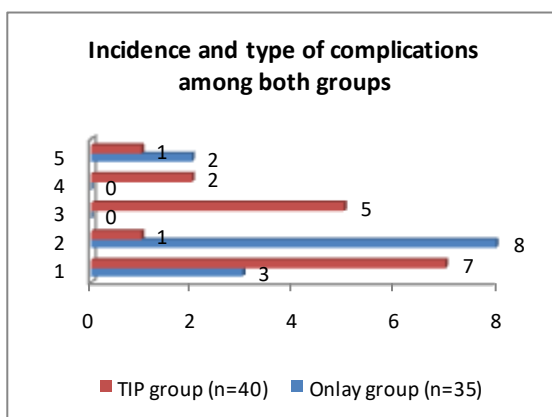
Onlay group had 34% overall complication rate. Fistula was the commonest complication followed by dehiscence and stricture, with only one case of meatal stenosis and five cases of dehiscence. The fistula rate, dehiscence rate are higher in onlay flap group but dehiscence is only statistically significant. Meatal Stenosis rate is higher in FIP group and this is also statistically significant stricture formation rate is somewhat higher in onlay group but there is no statistical significance for this complication. Delayed fistula rate is higher in TIP group but there is no statistical significance.

Complications

As regard the overall complications, the TIP group had a total incidence of complications 28%. Meatal stenosis and fistula were the frequent complications. The

Table 2 : Incidence and type of complications among both groups

	TIP group (n=40) No (%)	Onlay group (n=35) No (%)	P value	Significance
Fistula	3 (8%)	7 (20%)	0.0174	Non significant
Meatal stenosis	8 (20%)	1 (3%)	0.032	Significant
Dehiscence	0 (0%)	5 (14%)	0.019	Significant
Stricture	0 (0%)	2 (6%)	0.214	Non significant
Delayed Fistula	2 (5%)	1 (3%)	1.000	Non significant



Uroflowmetry studies were done 6 months postoperatively for all patients. 6 cases were excluded in the TIP group and 11 cases in the Onlay group due to presence of complications. In the TIP group 28 cases out of 40 (70%) had normal peak flow rate, four cases (10%) had equivocal flow and 8 cases (20%) had obstructed flow (Table 3). In the Onlay group 35 patients were studied; 26 (74%) had normal peak flow rate and 8 patients had equivocally obstructed flow rate (23%). Comparing results in both groups showed statistical difference in obstructed flow patients and showed higher rate in TIP group.

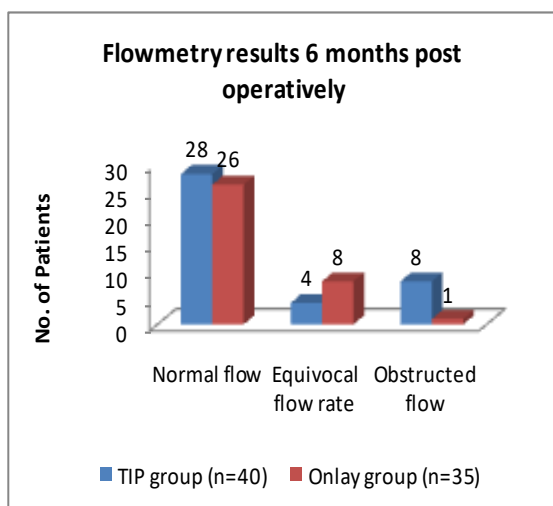
Uroflowmetry study

Cases with equivocal or obstructed flowmetry pattern responded to dilatation and /or meatotomy. They all revert to normal

flow pattern on the follow up tests done 12 month postoperatively.

Table 3 : Flowmetry results 6 months post operatively

	TIP group (n=40) No (%)	Onlay group (n=35) No (%)	P value	Significance
Normal flow	28 (70%)	26 (74%)	0.798	Non significant
Equivocal flow rate	4 (10%)	8 (23%)	0.206	Significant
Obstructed flow	8 (20%)	1 (3%)	0.032	Significant



DISCUSSION

The treatment of hypospadias has been changing during the last decades in order to achieve normal functional and cosmetic appearance of the urethral meatus. Two of the widely practiced techniques are the TIP and single faced Onlay preputial island flap. In the last decade, since the urethral plate incision urethroplasty was presented by Snodgrass, [10-12] it gained wide popularity due to its ease and vertically oriented appearance of the meatus.

In this study all patients were preselected so that they would all meet the criteria for TIP procedure, namely a healthy urethral plate suitable for tubularization. Inclusion criteria also included cooperative toilet trained children who would be able to undergo uroflowmetry studies for functional assessment. None of the cases had severe chordee. Moreover artificial erection test was performed intraoperatively.

2 In 6 cases there were curvature between 20-30 and dorsal plication was needed in 4 cases (2 in each group).

In recent years, one of the important considerations in hypospadias surgery is the

final cosmetic result. The ultimate goal is a penis not only functionally normal but also appears to have been only circumcised. In this study slit-like vertical shape of the meatus and the glans could be achieved in the TIP group in the majority of cases (78%), in contrast to only 34% of cases in the Onlay group. This usually encountered horizontally oriented rounded meatus is one of the main criticisms for this procedure especially when the ventral glans is flat. This difference in the shape of the meatus was statistically significant in the favor of TIP group (P value= 0.002).

On the other hand there was no statistical significant difference between both groups as regard the site of the meatus. Terminal position was achieved in 83% of cases in the TIP versus 77% of cases in the Onlay group.

Penile rotation as a postoperative complication was reported by Figueroa and Fitzpatrick [5] who had moderate penile torsion in 1/63 cases of their TIP cases postoperatively. In this study 3 cases in the Onlay group had mild torsion and none of TIP group had this complication. The authors believe that the fear of injuring the vascular pedicle in the Onlay flap does not allow extensive pedicle dissection resulting in torsion. However, Van der Werff and Ultee [7] in their long term follow up for hypospadias series could not clear out whether the operations have caused worsened or diminished penile rotation. Complications are common after hypospadias repair, ranging from fistulae to complete loss of the neourethra requiring total reconstruction. The incidence of complications was 28% in the TIP group (10% fistula, 0% stricture, 10% meatal stenosis, 5% delayed fistula and 2.5%

complete dehiscence). This is higher than that is reported by Sozubir and Snodgrass [13] (fistula 9%, glandular dehiscence 4% and meatal stenosis in 1%) while Cheng [4] had in his 540 cases, only 1% overall incidence of complications in his TIP series with fistula 0.6% followed by meatal stenosis 0.3%. In this study, the Onlay group had overall 34% complication rate which is higher than that is reported by Keating and Rich [9] (15%) and Weiner [14] (22%). In this work Fistula was more common in the Onlay group (14%). The same was observed by Weiner who had 17% incidence of fistula in his study. The Onlay island flap though having the versatility of widening the urethral caliber, but it carries the disadvantage of having two suture lines adding more risk for fistulae formation. The incidence of complication however, was statistically insignificant between the two groups. Uroflowmetry is a non-invasive diagnostic method well accepted by children and is uninfluenced by stress. In this study the Qmax values were normal in the majority of cases in both groups at 6 months postoperatively (80% in the TIP versus 77% in the Onlay group). The difference was statistically insignificant. In the Tip group 20% had equivocal and obstructed flow, where as 23% of the Onlay group had equivocal flow on the first test. Such cases in both groups were managed by dilatation and/or meatotomy and all had normal flow on the follow up test done at 12 months postoperatively. Hammouda [6] found that 68% of his TIP cases had normal Qmax, 6 months postoperatively while 32% had equivocal flow. The flowmetry was well tolerated by children.

Garibay [9] concluded that it is an important tool to evaluate the hypospadias surgical results and to detect asymptomatic strictures. It allows the study of natural urination and could significantly reduce the frequency of calibration and postoperative urethral dilation which is an invasive, poorly tolerated procedure.

CONCLUSIONS

From this study it is concluded that both techniques resulted in an acceptable anterior position of the neomeatus and had comparable complications rates.

Uroflowmetry studies showed functional difference between the two procedures, it was an objective, reliable and repeatable investigation in children and could replace urethral calibration for postoperative functional follow up. Though both techniques found logical alternative for the repair for this deformity. Onlay flap repair have more fistula rate and dehiscence rate and also takes more operative time and technical expertise and complications are difficult to manage. The dehiscence rate in onlay is statistically significance. TIP repair has more meatal stenosis rate and also statistically significant which is simpler to manage and technically easy and takes less operative time. So the author prefer TIP repair as being technically easier with simple complications, superior cosmetic outcome and satisfying vertical slit like meatus.

REFERENCES

1. Bates P, Bradley WE, Glen E, et al. The standardization of terminology of lower urinary tract function. J Urol 121:551-554, 1979
2. Bhattacharya S: A modified tubularised incised plate urethroplasty technique and a revised hypospadias algorithm. Indian J. Plast Surg. 2010 Jan; 43(1): 21-7.
3. Borer JG, Bauer SB, Peters CA, Diamond DA, Atala A, Cilento BG Jr, et al.: Tubularized incised plate urethroplasty: expanded use in primary and repeat surgery for hypospadias. J Uro. 2001; 165: 581-5.
4. Cheng EY, Vemulapalli SN and Kropp BP. Snodgrass hypospadias repair with vascularised dartos flap: The perfect repair for virgin cases of hypospadias? J Urol. 168:1723-26, 2002
5. Figueroa TE, Fitzpatrick KJ.: Transverse preputial flap for ventral penile skin coverage in hypospadias surgery (abstract) Tech Urol. 4:83-6, 1998

6. Hammouda HM, El Ghonemi A, Bagli DJ, McLoie GA, Khoury AE. Tubularized incised plate repair: Functional outcome after intermediate follow up. J Urol 169: 331-3, 2003
7. J. F. A. van der Werff and J. Ultee Long-term follow-up of hypospadias repair British Journal of Plastic Surgery 53: 588-592, 2000
8. Keating AK and Mark AR : Onlay and Tubularized Preputial Island Flap in Ehrlich RM, Alter G J (eds) Reconstructive and Plastic Surgery of the External genitalia- Adult and Pediatric. WB Saunders.1999, pp 70-78
9. Garibay JT, Reid C, Gonzalez R: Functional evaluation of the results of hypospadias surgery with uroflowmetry. J Urol 154:835-6, 1999
10. Snodgrass W, Koyle M, Manzoni G, Hurwitz R. Caldamone A. Ehrlich R: Tubularized incised plate hypospadias repair for promixal hypospadias. J. Urol. 1998: 159: 2129-31.
11. Snodgrass W: Tubularized, incised plate urethroplasty for distal hypospadias. J Urol 151:464, 1994
12. Snodgrass WT, Lorenzo A: Tubularized incised-plate urethroplasty for proximal hypospadias. Br J UrolInt 89:90- 93, 2002
13. Sozubir S. and Snodgrass W: A new algorithm for Primary Hypospadias Repair based on TIP Urethroplasty. J PedSurg 35:1453-55, 2000
14. Weiner JS, Sutherland RW, Roth DR et al: Comparison of onlay and tubularized island flaps of inner preputial skin for the repair of proximal hypospadias. J Urol 158:1172-74, 1997

How to cite this article: Tripathi RK, Sahu SS, Singh S et.al. Comparison between tubularised incised plate urethroplasty with preputial flap urethroplasty in anterior and mid penile hypospadias. International Journal of Research and Review. 2018; 5(9):130-135.
