

Functional Outcomes of Arthroscopic Bankart Repair with Remplissage Versus Latarjet Procedure in Recurrent Anterior Shoulder Instability: A Systematic Review

Anak Agung Ngurah Arya Yugadhyaksa^a, Komang Mahendra Laksana^b,
Anak Agung Yukta Panditama^c

^a General Practitioner, Faculty of Medicine, Warmadewa University, Bali, Indonesia

^b Sport Consultant, Department of Orthopaedic and Traumatology, Wangaya General Hospital, Bali, Indonesia

^c General Practitioner, Faculty of Medicine, Warmadewa University, Bali, Indonesia

Corresponding Author: Anak Agung Ngurah Arya Yugadhyaksa

DOI: <https://doi.org/10.52403/ijrr.20260344>

ABSTRACT

Background: Recurrent anterior shoulder instability remains a challenging condition, particularly in the presence of engaging Hill–Sachs lesions and glenoid bone loss. Arthroscopic Bankart repair with remplissage and the Latarjet procedure are widely employed surgical solutions, but direct comparisons of their functional outcomes and complication profiles remain limited.

Objective: To systematically review the available evidence comparing functional outcomes, recurrence rates, and complications between arthroscopic Bankart repair with remplissage and the Latarjet procedure in patients with recurrent anterior shoulder instability.

Methods: A systematic literature search was conducted in PubMed, Cochrane Library, and ScienceDirect. Eligible studies included comparative clinical investigations of remplissage versus Latarjet reporting patient-reported outcome measures, return to sport, range of motion, recurrence, and

complications. Eight studies met inclusion criteria. Data were synthesized qualitatively in accordance with PRISMA 2020 guidelines.

Results: Both remplissage and Latarjet procedures yielded substantial postoperative improvements in validated functional scores, high patient satisfaction, and return-to-sport rates often exceeding 70%. Recurrence rates were comparably low, generally below 10%, with few revision procedures required. Distinct functional and safety profiles were observed: remplissage was associated with modest external rotation deficits, whereas Latarjet preserved or improved motion but carried a higher complication burden, including graft nonunion, hardware-related issues, and neurovascular risks.

Conclusion: Arthroscopic Bankart repair with remplissage and the Latarjet procedure both provide durable stabilization with significant functional gains. Surgical selection should be tailored to patient profile and bone loss severity: remplissage for engaging Hill–Sachs lesions with subcritical glenoid loss, and Latarjet for critical bone defects, collision

athletes, or revision cases. Further high-quality trials are needed to confirm long-term outcomes and refine patient-specific indications.

Keywords: Anterior shoulder instability; Bankart repair; Remplissage; Latarjet procedure; Functional outcomes

INTRODUCTION

Anterior shoulder instability represents one of the most common shoulder pathologies encountered in orthopedic practice, particularly among young adults and athletes engaged in contact or overhead sports.¹ The shoulder joint's exceptional range of motion comes at the expense of intrinsic stability, relying heavily on the congruity of the glenohumeral articulation, labral integrity, capsuloligamentous structures, and dynamic muscular control. Following a first traumatic dislocation, recurrence is frequent, with rates varying from 20% to 70% depending on patient age, activity level, and anatomical risk factors.¹ In young athletes, particularly those involved in high-risk sports such as rugby, wrestling, or overhead throwing, the likelihood of recurrent instability is considerably higher, underscoring the importance of timely recognition and appropriate management.

The underlying pathoanatomy of anterior instability is complex. Traumatic dislocations frequently lead to detachment of the anteroinferior labrum, classically described as a Bankart lesion.² In many cases, an impression fracture of the posterolateral humeral head - the Hill-Sachs lesion - occurs as the humeral head impacts against the anterior glenoid rim.² Burkhart and De Beer were among the first to emphasize that the size and engagement of these defects, in combination with glenoid bone loss, are critical determinants of surgical success.³ Once bone loss reaches certain thresholds, the concavity-compression mechanism is

insufficient to prevent engagement, leading to repeated episodes of instability. Over time, this cycle not only impairs function but can also accelerate degenerative changes in the glenohumeral joint, significantly affecting quality of life.⁴

The treatment paradigm for anterior instability has evolved considerably over the past four decades. Arthroscopic Bankart repair has become the standard of care for patients with soft-tissue lesions and minimal glenoid bone loss, as it offers a minimally invasive approach with preservation of anatomy and relatively straightforward rehabilitation.⁵ However, evidence suggests that outcomes deteriorate in the presence of "subcritical" glenoid bone loss, even as low as 13–15%, or when there is an "off-track" Hill-Sachs lesion.⁶ In such situations, the biomechanical compromise exceeds the stabilizing capacity of an isolated Bankart repair, necessitating augmentation procedures. Among these augmentation options, two strategies have gained prominence. The remplissage technique, described by Wolf in 2007, involves in-filling the Hill-Sachs defect with the infraspinatus tendon and posterior capsule, thereby converting the intra-articular defect into an extra-articular one.⁷ When combined with a Bankart repair, this arthroscopic technique addresses both labral detachment and the humeral head defect, offering improved stability in cases of engaging Hill-Sachs lesions without the morbidity of coracoid transfer.⁸ Clinical studies and biomechanical investigations have shown that remplissage effectively prevents engagement and substantially reduces recurrence rates, with relatively few complications.⁸ Nevertheless, concerns remain regarding its potential to limit external rotation, particularly in throwing or overhead athletes, where subtle motion deficits may impair performance.

By contrast, the Latarjet procedure, originally described in 1954, involves transferring the

coracoid process with its attached conjoint tendon to the anterior glenoid rim.⁹ This technique provides a so-called “triple-blocking effect”: bony augmentation of the glenoid, a sling effect from the conjoint tendon during abduction and external rotation, and capsular reinforcement through coracoacromial ligament suturing.⁹ The Latarjet has consistently demonstrated low recurrence rates, especially in patients with critical bone loss or failed prior stabilization procedures. However, the operation is technically demanding, and its complication profile is not trivial. A systematic review by Griesser et al. reported overall complication rates approaching 30%, including neurovascular injuries, graft nonunion, and postoperative arthropathy.¹⁰ These risks, along with the invasiveness of the procedure, have prompted ongoing debate regarding its use as a primary procedure in patients with subcritical bone loss.

Controversy therefore remains regarding the optimal surgical strategy for recurrent anterior instability in the setting of engaging Hill–Sachs lesions or subcritical glenoid bone loss. Proponents of remplissage argue that it offers a minimally invasive solution with fewer complications, while critics caution against the risk of external rotation limitation and uncertain performance in collision athletes.^{6–8} Advocates of the Latarjet emphasize its durability and biomechanical advantages, yet its higher risk profile and technical complexity may limit its appeal in certain populations.^{9,10} Furthermore, the precise threshold at which remplissage ceases to be effective and Latarjet becomes mandatory remains ill-defined, with definitions of “critical” and “subcritical” bone loss still evolving.⁶

Given these uncertainties, systematic comparison of these two techniques is necessary to guide evidence-based decision-making. Several comparative studies have emerged in recent years, but results remain

heterogeneous, with differences in study design, populations, and outcome measures complicating interpretation.^{6–8} Functional outcomes, particularly patient-reported outcome measures (PROMs) such as Rowe, ASES, WOSI, and Constant scores, as well as return to sport and shoulder range of motion, are of particular clinical importance. Equally critical are recurrence rates, revision surgeries, and complications, which directly influence long-term success.

The present systematic review aims to consolidate and critically analyze the available evidence comparing arthroscopic Bankart repair with remplissage versus the Latarjet procedure for recurrent anterior shoulder instability. By focusing on both functional outcomes and complications, this review seeks to clarify the relative merits of each approach, define their clinical indications, and identify areas where further high-quality research is warranted.

Methods

Protocol

This systematic review was conducted in accordance with the Preferred Reporting Items for Systematic Reviews and Meta-Analyses (PRISMA) 2020 statement.

Search Strategy

A comprehensive literature search was performed across three major electronic databases: PubMed/MEDLINE, Cochrane Library, and ScienceDirect. The search was conducted from database inception to the latest available date and restricted to English-language publications. The primary search terms combined keywords and Boolean operators relating to the intervention and comparator:

(Arthroscopic Bankart OR Bankart repair OR Bankart procedure) and (Remplissage) and (Latarjet).

To maximize sensitivity, additional terms including anterior shoulder instability and

shoulder dislocation were incorporated. The reference lists of included studies and relevant reviews were manually screened to identify any additional eligible articles not captured in the initial search.

Eligibility Criteria

Studies were eligible if they met the following predefined criteria:

- Population: Patients of any age with recurrent anterior shoulder instability, with or without subcritical glenoid bone loss and/or engaging Hill–Sachs lesions.
- Intervention: Arthroscopic Bankart repair combined with remplissage.
- Comparison: Latarjet procedure (open or arthroscopic).
- Outcomes: Primary outcomes included functional results measured by patient-reported outcome measures (PROMs) such as Rowe score, American Shoulder and Elbow Surgeons (ASES) score, Western Ontario Shoulder Instability Index (WOSI), Constant score, as well as return-to-sport rates and shoulder range of motion (particularly external rotation). Secondary outcomes included recurrence or redislocation, revision surgery, and procedure-related complications.
- Study Design: Randomized controlled trials, prospective or retrospective comparative cohort studies, and case–control studies. Case reports, review articles, technical notes, cadaveric or biomechanical studies, and studies lacking a comparator group were excluded.

Data Extraction

Two reviewers independently screened the titles and abstracts of all retrieved records for

relevance. Full texts of potentially eligible studies were then assessed in detail against the inclusion criteria. For each included study, data were extracted using a standardized form, including: first author, year of publication, country/setting, study design, sample size, inclusion/exclusion criteria, intervention and comparator details, outcome measures, duration of follow-up, and key findings. Any discrepancies were resolved through discussion and, if necessary, consultation with a third reviewer.

Risk of Bias Assessment

Risk of bias in individual studies was assessed according to study design. Randomized controlled trials, if present, were evaluated using the Cochrane Risk of Bias 2.0 tool. Non-randomized studies were appraised using the Newcastle–Ottawa Scale (NOS), focusing on selection, comparability, and outcome domains. Risk-of-bias assessments were conducted independently by two reviewers, with disagreements resolved by consensus.

Data Synthesis

Given the anticipated clinical and methodological heterogeneity across included studies - particularly regarding patient populations, bone loss thresholds, surgical techniques, and outcome measures - a qualitative synthesis was planned. Extracted data were tabulated to facilitate structured comparison of study characteristics and results. Narrative synthesis emphasized functional outcomes, recurrence rates, and complications. Meta-analysis was not performed due to the heterogeneity of available data and variability in outcome reporting.

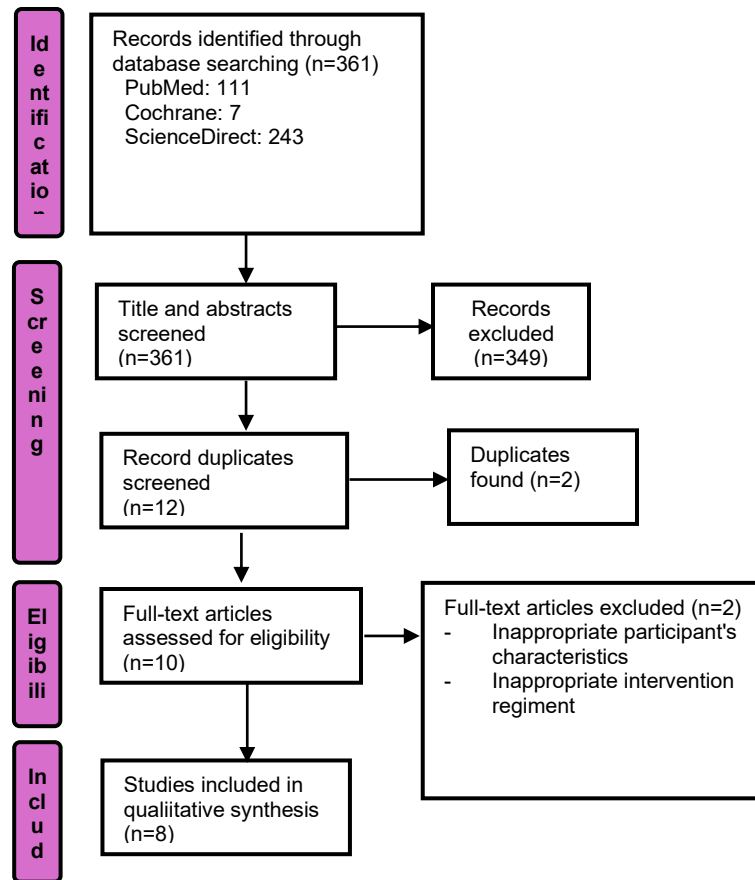


Figure 1. Diagram flow of literature search strategy for this systematic review

First Author (Year)	Country / Setting	Study Design	Population (N, inclusion criteria)	Intervention: Arthroscopic Bankart + Remplissage	Comparison: Latarjet (open/arthroscopic)	Outcomes Measured (PROMs, ROM, return to sport, recurrence, complications)	Follow-up Duration	Summary of Findings / Key Points
Yang et al. (2018)	USA (Kaiser Permanente Los Angeles Medical Center & Univ. of Connecticut Health Center)	Retrospective cohort (Level III evidence)	189 patients with recurrent anterior instability, off-track Hill-Sachs lesion, <25% glenoid bone loss. Group A: 98 remplissage; Group B: 91 modified Latarjet. Predominantly male (95%), mean age ~29 years.	Arthroscopic Bankart repair + remplissage	Modified Latarjet procedure (open)	SANE, WOSI, VAS pain, ROM (ER, IR, flexion), recurrence, revision, complications. Subgroup analyses: prior instability surgery, glenoid bone loss >15%, collision/contact athletes.	Mean 3.2 years (range 2–12)	Both procedures achieved satisfactory results in the general population. Remplissage group had slightly higher pain (VAS 2.2 vs 1.55) and more IR limitation, but similar PROMs (SANE, WOSI) compared with Latarjet. Complication rate was significantly higher with Latarjet (12.1% vs 1%). Subgroup analyses showed Latarjet superior in revision cases, collision/contact athletes, and patients with >10–15% glenoid bone loss (lower recurrence and revision rates, better WOSI scores).
Cho et al. (2015)	South Korea (Kyung Hee University Hospital, Seoul)	Retrospective case-control (Level III)	72 shoulders with recurrent anterior instability and large engaging Hill-Sachs lesion, no significant glenoid bone loss (<25%). Group A: 37 remplissage + Bankart; Group B: 35 Latarjet. Mean age 24.8 ± 9.0 yrs vs 27.8 ± 7.9 yrs.	Arthroscopic Bankart repair with remplissage	Open Latarjet procedure	Rowe score, UCLA score, VAS for pain, ROM (ER, IR, flexion), muscle strength, recurrence, complications, return to preinjury sports activity. Imaging (MRA/CT) for structural outcomes.	Mean 24.7 ± 9.5 months (remplissage) vs 30.4 ± 11.2 months (Latarjet)	Both procedures safe and reliable with low recurrence (5.4% vs 5.7%). PROMs (Rowe, UCLA) improved similarly, no significant differences. Remplissage group had ~8° loss in ER at side; Latarjet group showed greater ROM restrictions (ER at side, ER at 90°, IR posterior). Muscle strength preserved or improved in both groups. Latarjet had significantly higher complication rate (14.3% vs 0%), including screw impingement, neurologic injury, postoperative stiffness, fibrotic union. Return-to-sport rates comparable.
Abouelsoud & Abdelrahman (2015)	Egypt (Ain Shams University Hospitals, Cairo)	Prospective comparative study	32 patients (29M, 3F), mean age 28.2 yrs, recurrent anterior shoulder instability with large engaging Hill-Sachs lesion. Excluded if glenoid bone loss >20%, SLAP lesion, cuff tear, or prior surgery. Group 1: 16 Latarjet; Group 2: 16 remplissage + Bankart repair.	Arthroscopic Bankart repair with remplissage using 4 anchors	Open modified Latarjet (congruent-arc technique, coracoid transfer fixed with 2 screws)	Rowe score, ROM, VAS for pain, recurrence, complications, operative time, implant cost	Mean 31.3 months (range 24–40)	Both procedures equally effective in preventing recurrence; only 1 redislocation (Latarjet group). Rowe scores improved significantly in both (Latarjet: 28.75 → 84.62; Remplissage: 26.12 → 86.62). ER in abduction limited in both (15° Latarjet vs 10° remplissage). Early postop pain higher in Latarjet (VAS 3.9 vs 2.4). No major complications. Remplissage much more costly (~10× implant cost) and had longer operative time (~102 vs 58 min).
Saremi et al. (2021)	Iran (Hamadan Univ. of Medical Sciences)	Quasi-experimental comparative study	128 patients with recurrent anterior shoulder dislocation, operated 2011–2016. Group A: 34 Bankart repair; Group B: 68 Bankart + remplissage; Group C: 26 open Latarjet. Inclusion: ≥4 yrs postop follow-up, no contralateral pathology.	Arthroscopic Bankart repair with remplissage	Open Latarjet procedure (indicated if >25% glenoid bone loss)	VAS for pain, apprehension test, ROM (ER neutral & 90° abduction), recurrence (re-dislocation), complications	Mean 6.2 years (range 4–9)	All three techniques achieved satisfactory results. Redislocation: 1 case (1.5%) in remplissage group. Apprehension positive in 5.8% (Bankart), 11.7% (remplissage), 0% (Latarjet). ROM restriction greatest in Latarjet group (ER loss ~18.5° at side, 16.6° at 90° abduction). Remplissage did not cause significant additional ER restriction compared with Bankart. VAS pain improved significantly in all groups (final: Bankart 0.29; remplissage 0.76; Latarjet 0.38). Authors note Latarjet provides excellent stability but induces more ROM restriction, while remplissage may be less effective in patients with concomitant glenoid bone loss.
Hurley et al. (2022)	USA (NYU Langone Health, New York)	Retrospective cohort (Level III evidence)	67 patients with anterior instability + engaging Hill-Sachs lesion, 2011–2019. Group A: 41 ABRR; Group B: 26 arthroscopic Latarjet. All skeletally mature, >24 months follow-up. AL group	Arthroscopic Bankart repair + remplissage (two anchors for remplissage,	Arthroscopic Latarjet procedure (Lafosse technique with subscapularis split, fixation with	WOSI, VAS pain, Subjective Shoulder Value (SSV), SIRSI, satisfaction, willingness to undergo surgery again, RTP,	Mean 55 months (~4.6 yrs)	Both procedures yielded excellent outcomes with no significant differences in PROMs (WOSI ~22% vs 28%, VAS 0.9 vs 1.4, SSV 78 vs 75, SIRSI ~69 vs 63). Satisfaction high (>80%). RTP ~61% vs 67% (NS); RTW 100% both.

			had more glenoid bone loss (19.1% vs 7.3%) and prior surgeries (42% vs 5%).	3+ anchors for Bankart)	2 screws)	RTW, recurrent instability, complications		Recurrence: 12.2% ABRR vs 7.7% AL (NS). Complications: ABRR 4.9% (anchor issue), AL 7.7% (graft fracture needing revision, suspected infection). Authors conclude both are reliable, but caution against ABRR in severe glenoid bone loss or failed prior stabilization.
Horinek et al. (2022)	Multicenter (USA, Argentina, Switzerland, France)	Multicenter retrospective cohort (Level III evidence)	47 patients (22 REMP, 25 Latarjet) with anterior instability and >15% glenoid bone loss; excluded <15% GBL, revisions, missing baseline data. Mean age 27.5 yrs, 87% male, 72% overhead/contact athletes.	Arthroscopic Bankart repair + remplissage (3–4 anchors Bankart, 2 anchors remplissage)	Open Latarjet (coracoid transfer with 2-screw fixation)	SANE, WOSI, VAS pain, ROM (FF, ER, IR), return to same sport, satisfaction, recurrence, complications	Mean 2.3 years (range 2–4.5)	Both groups showed significant PROM improvement (SANE ~95–100, VAS pain ~0.3–1.0, WOSI ~104–218). Return to same sport high (87% REMP vs 88% Latarjet), satisfaction ~96% both. No recurrent dislocations in either group. Latarjet yielded +10° ER gain, REMP –4° ER loss (p=0.017). One infected hematoma (Latarjet); none in REMP. Authors suggest remplissage may be a viable option in >15% GBL, though ER deficit may matter in overhead athletes.
Horinek et al. (2022)	Multicenter (USA, Argentina, Switzerland, France)	Multicenter retrospective comparative study (Level III)	258 patients (70 ABR; 188 Latarjet), primary anterior instability, operated 2013–2019. Inclusion: primary stabilization with ABR or Latarjet, ≥2 yrs follow-up. Exclusion: revisions, missing baseline data. Mean age 26.7 yrs, 84% male. ABR group had higher GBL (12.3% vs 7.6%) and more off-track lesions (23% vs 13%).	Arthroscopic Bankart repair + remplissage (3–4 anchors Bankart, 2 remplissage anchors)	Open Latarjet (coracoid transfer with 2 screws, deltopectoral approach)	WOSI, SANE, VAS pain, ROM (FF, ER, IR), recurrence, return to sport, satisfaction, complications	Mean 2.5 yrs (range 2–4.5)	Both groups showed significant PRO improvement. ABR achieved greater gains in VAS (–1.9 vs –0.9, p=0.019) and WOSI (–1096 vs –805, p<0.001). SANE, VAS, WOSI PASS/MCID achievement favored ABR. ABR had ER loss (–4°) while Latarjet gained ER (+19°, p<0.001). Return to sport overall similar, but overhead/contact athletes higher with ABR (91.5% vs 72.7%, p=0.007). Satisfaction ~96% vs 90% (NS). Recurrence very low and similar (1.4% ABR vs 3.2% Latarjet). Complications: none in ABR, 5.9% in Latarjet (hardware, infection, neuropraxia). Authors conclude ABR provides equal or superior functional outcomes with fewer complications, but with ER loss that may impact overhead athletes.
Bah et al. (2018)	France & Morocco (2 centers)	Retrospective comparative cohort (Level III)	86 patients with chronic anterior instability + significant Hill–Sachs lesion (≥30% humeral head involvement or engaging lesion). Matched cohorts: 43 Bankart + remplissage, 43 open Latarjet. Excluded if >30% glenoid bone loss, multidirectional instability, rotator cuff tear.	Arthroscopic Bankart repair with remplissage (posterior capsulodesis + infraspinatus tenodesis)	Open Latarjet coracoid transfer with screw fixation	SSV, Rowe, Walch–Duplay scores; VAS pain; ROM (ER1/ER2, abduction, IR); recurrence, revision, apprehension (Fowler’s test)	Mean 47 months (range 24–67)	Recurrence rates similar (9.3% BR vs 11.2% Latarjet, p=0.67). Functional scores significantly improved in both groups (Rowe ~90, Walch–Duplay ~92, SSV ~87–89). Residual pain more common after BR (21% vs 9%, p=0.023). External rotation restriction greater in BR (loss of ~10° ER1, ~13° ER2, p<0.001) compared with Latarjet (loss ~3.7° ER1, ~0.3° ER2, NS). Revision rare (1 per group). Both procedures reliable; authors note Latarjet preserves ER better, whereas remplissage carries risk of stiffness and persistent pain.

Table 1. Characteristics and results of the included studies

RESULTS

Study Selection

The systematic search strategy identified a total of 361 potentially relevant records: 111 from PubMed, 7 from the Cochrane Library, and 243 from ScienceDirect. After removal of duplicates ($n=2$), 359 unique records remained for title and abstract screening. During this phase, 349 studies were excluded for reasons including unrelated surgical procedures, absence of direct comparison between remplissage and Latarjet, biomechanical or cadaveric design without clinical outcomes, and narrative or technical notes without original data. Ten studies underwent full-text assessment. Following detailed evaluation, two were excluded — one for inappropriate participant characteristics (mixed pathology with no stratification for anterior instability) and another for an intervention regimen that did not correspond to either arthroscopic Bankart repair with remplissage or the Latarjet procedure. As a result, eight studies fulfilled all eligibility criteria and were included in the final qualitative synthesis. The process of study identification, screening, eligibility, and inclusion is summarized in the PRISMA flow diagram, which highlights the rigorous filtering and transparent methodological approach applied in this review.

Characteristics of Included Studies

The eight included studies were published between 2015 and 2022, reflecting contemporary surgical practice and outcomes reporting. Together, they encompass diverse patient populations treated across North America, Europe, Asia, and the Middle East, underscoring the global relevance of this clinical problem. Study designs were predominantly retrospective or prospective comparative cohorts (Level III evidence), though one study was conducted in a quasi-experimental manner. Sample sizes varied widely: smaller single-center investigations enrolled as few as 32 patients, whereas larger multicenter analyses involved up to

258 participants. Collectively, the total number of included patients exceeded 800, providing a broad clinical spectrum for comparison.

Patient inclusion criteria were generally consistent across studies, focusing on individuals with recurrent anterior shoulder instability following traumatic dislocation events. Many studies specifically required the presence of an engaging Hill–Sachs lesion or subcritical glenoid bone loss, conditions known to compromise the success of isolated Bankart repair. Patients with massive glenoid bone loss (>25 – 30%), multidirectional instability, large rotator cuff tears, or prior failed stabilization surgery were typically excluded, ensuring the comparability of cohorts.

The interventions of interest were arthroscopic Bankart repair combined with remplissage versus the Latarjet procedure, performed either through open or arthroscopic approaches. Although the surgical principles were uniform, technical nuances varied. For remplissage, surgeons employed posterior capsulotenodesis of the infraspinatus tendon into the Hill–Sachs defect with one or two anchors, in combination with standard anterior labral repair using multiple suture anchors. In contrast, the Latarjet procedures included both classic and congruent-arc techniques, most commonly with coracoid fixation achieved via two screws. These technical details may influence outcomes such as external rotation, complication rates, and graft union, which were reported variably across the studies.

Follow-up duration ranged from two to more than six years, with several studies providing mid- to long-term data. This breadth of follow-up strengthens the conclusions by demonstrating durability of outcomes, while also allowing observation of late complications such as graft resorption, postoperative stiffness, or recurrent instability.

Functional Outcomes

Functional outcomes were consistently reported across studies using validated patient-reported outcome measures (PROMs), including Rowe, UCLA, ASES, WOSI, Constant, and Subjective Shoulder Value (SSV). Across all eight studies, both remplissage and Latarjet groups showed substantial improvements from baseline to final follow-up, with postoperative scores often reaching thresholds considered clinically meaningful. For example, Rowe and Constant scores commonly improved into the 80–90 range, while WOSI and SANE demonstrated significant reductions in symptom burden and improved function. Importantly, no study demonstrated statistically significant superiority of one technique over the other in overall PROM improvement, underscoring that both approaches are viable in appropriately selected patients.

Return to sport (RTS) was an important metric reported in nearly all studies. Overall RTS rates were high, often exceeding 70% and in some cohorts reaching 85–90%. However, subtle differences were noted in the type of sport and level of play achieved postoperatively. Several authors observed that remplissage was associated with limitations in high-demand overhead or throwing athletes due to a measurable reduction in external rotation. For example, Yang et al. and Horinek et al. reported that although remplissage achieved excellent stability and PROMs, athletes requiring maximal external rotation for performance (e.g., baseball pitchers, volleyball players) may be disadvantaged compared to those treated with the Latarjet procedure. Conversely, the Latarjet was associated with preserved or improved external rotation and a higher proportion of patients returning to the same pre-injury sport level, though these benefits must be weighed against its higher complication rate.

Range of motion (ROM), particularly external rotation (ER), was the most consistently affected functional domain. Remplissage was repeatedly linked with

mild to moderate ER deficits, typically in the range of 5–15 degrees. These deficits were statistically significant in some studies but of unclear clinical relevance in recreational athletes or non-overhead populations. In contrast, several Latarjet cohorts demonstrated preserved or even increased ER at final follow-up, likely due to restoration of the glenoid arc and dynamic sling mechanism. Internal rotation and forward flexion were generally unaffected by either procedure, and muscle strength outcomes were comparable.

In summary, both remplissage and Latarjet provided marked improvements in function, pain relief, and patient satisfaction. Differences emerged mainly in ROM profiles and sport-specific outcomes, with remplissage associated with small but consistent ER loss and Latarjet offering broader restoration of motion.

Recurrence and Revision

Recurrence of dislocation or symptomatic instability was a critical endpoint across all studies. Both remplissage and Latarjet procedures yielded low recurrence rates, generally <10%. In smaller single-center studies, recurrence was observed in only one or two patients per group, while larger multicenter series reported recurrence rates ranging from 1.5% to 12%, with no significant differences between procedures. For instance, Bah et al. reported recurrence rates of 9.3% for remplissage and 11.2% for Latarjet, while Hurley et al. observed similar recurrence profiles in their arthroscopic Latarjet and remplissage cohorts.

Revision surgery was uncommon, typically reported in isolated cases. Reasons for revision included graft-related issues in the Latarjet group, such as screw impingement or nonunion, and persistent instability after remplissage in patients with underappreciated glenoid bone loss. Importantly, no study identified a consistent need for revision disproportionately associated with either technique, supporting

the reliability of both approaches when indications are carefully observed.

Complications

Complication rates demonstrated the clearest difference between procedures. The Latarjet procedure, whether performed via open or arthroscopic approach, was associated with a higher incidence of complications. These included graft nonunion, hardware-related problems, hematoma or infection, and transient neurologic injury. The overall reported complication rate in some series exceeded 10%, echoing findings from prior systematic reviews highlighting the technical challenges and inherent risks of the Latarjet. Despite these risks, most complications were manageable, and long-term graft survival remained high.

In contrast, arthroscopic Bankart repair with remplissage demonstrated a more favorable safety profile. Serious complications were rare, and most reports noted only mild issues such as stiffness, posterior shoulder discomfort, or small losses in external rotation. No study reported significant neurovascular injuries or infections related to remplissage. The trade-off for this safer profile was the aforementioned deficit in ER, which, although rarely disabling, may be relevant for high-level athletes.

Taken together, these findings suggest that remplissage offers a low-complication, minimally invasive solution that is particularly attractive for patients with engaging Hill–Sachs lesions and subcritical glenoid bone loss, while the Latarjet remains a robust option in cases with critical bone loss or failed prior stabilization but carries higher technical risk.

DISCUSSION

Key Findings in Context

This systematic review highlights that both arthroscopic Bankart repair with remplissage and the Latarjet procedure provide reliable and clinically meaningful improvements in patients with recurrent anterior shoulder instability. Across all eight

included studies, postoperative outcomes consistently demonstrated significant gains in validated patient-reported outcome measures, such as Rowe, Constant, ASES, and WOSI scores, accompanied by marked reductions in pain and apprehension. The improvements frequently surpassed accepted thresholds for clinical significance, underscoring that both procedures, when appropriately indicated, restore stability and function.^{5,8,11}

An equally important finding was the similarity in recurrence rates between the two techniques. Despite differences in surgical philosophy, both remplissage and Latarjet yielded redislocation rates that were generally below 10%. This aligns with contemporary series indicating that recurrence is no longer the predominant challenge in surgical stabilization; instead, functional recovery, return-to-sport capacity, and complication profiles have emerged as the critical differentiators.¹²

Yet, subtle but consistent distinctions were apparent. Remplissage was more often associated with external rotation deficits, typically between 5° and 15°, while the Latarjet procedure tended to preserve or even improve external rotation.¹³ Although these differences may not impact daily activities or recreational sports, they carry significant implications for high-performance overhead athletes, where even small motion restrictions can alter performance. In parallel, Latarjet was linked to higher complication rates, including graft nonunion, screw-related issues, and transient neurologic injuries.^{10,14,15} These findings echo prior systematic reviews and meta-analyses that have warned of the technical complexity and complication burden associated with coracoid transfer.¹⁰

Mechanistic Considerations

The differences in functional outcomes and complication rates are best understood through the biomechanical underpinnings of each procedure. The remplissage technique functions by filling the Hill–Sachs lesion with posterior capsule and infraspinatus

tendon, thereby preventing engagement with the anterior glenoid rim.⁷ This conversion of the defect to an extra-articular structure is highly effective in neutralizing instability but simultaneously results in posterior capsular tightening. Biomechanical studies confirm that this altered posterior restraint can restrict humeral head rotation, explaining the consistent external rotation deficits reported clinically.¹³ While minor in magnitude, these limitations may influence throwing kinematics, making remplissage less ideal for elite pitchers or tennis players. Conversely, the Latarjet procedure achieves stability via a tripartite mechanism: bony augmentation of the glenoid arc, a dynamic sling effect created by the conjoint tendon during abduction and external rotation, and capsular reinforcement from the coracoacromial ligament.⁹ This “triple-block” mechanism is unique in that it not only prevents engagement but also broadens the arc of stability, thereby often maintaining or improving external rotation. However, this biomechanical advantage is contingent on graft union and correct positioning. Malposition, nonunion, or hardware failure can destabilize the repair and predispose to complications.^{14,15} Thus, while the Latarjet addresses a broader spectrum of pathology, including significant glenoid bone loss, its technical complexity increases the risk profile.

Clinical Implications

For clinical practice, these findings reinforce the principle that neither remplissage nor Latarjet should be considered universally superior; rather, patient-specific factors should guide selection. In younger patients with engaging Hill–Sachs lesions and subcritical glenoid bone loss, arthroscopic Bankart repair with remplissage provides a minimally invasive solution with excellent functional outcomes and a relatively low complication rate.^{8,11,12} Surgeons must, however, counsel patients—particularly athletes in overhead sports—that a modest external rotation deficit is likely. In recreational athletes or non-

overhead laborers, this loss is usually inconsequential, making remplissage highly attractive.

By contrast, the Latarjet procedure retains its place as the treatment of choice in patients with critical glenoid bone loss (>20–25%), in collision athletes exposed to extreme forces, and in those with failed prior soft-tissue stabilization.^{9,15} Its ability to provide durable stability in these challenging populations is well documented, and recent reports of arthroscopic Latarjet techniques have aimed to mitigate complications while retaining biomechanical advantages.¹⁴ Nonetheless, the higher rate of surgical morbidity necessitates careful patient selection, thorough preoperative planning, and technical expertise.

From a broader perspective, these findings also support a trend toward individualized treatment algorithms that stratify patients based on bone loss thresholds, sport type, and prior surgical history. Such stratification ensures optimal matching of surgical technique to pathology, maximizing functional recovery while minimizing risk.

Limitations of the Evidence

Despite the encouraging findings, the current body of evidence is not without limitations. All included studies were Level III evidence, primarily retrospective or prospective cohort designs, inherently subject to selection bias, recall bias, and heterogeneity in surgical techniques. No randomized controlled trials directly comparing remplissage and Latarjet were identified, limiting the strength of inference. Study populations were diverse, spanning multiple continents, which enhances generalizability but also introduces variability in rehabilitation protocols, surgical instrumentation, and surgeon experience. Outcome measures were inconsistently reported, with some studies emphasizing PROMs while others prioritized radiographic or biomechanical parameters. Furthermore, follow-up durations, while frequently exceeding two

years, were insufficient to evaluate long-term risks such as glenohumeral osteoarthritis, which is particularly relevant in young patients undergoing stabilization procedures.⁴

Finally, subgroup analyses were rarely performed, leaving unanswered questions about outcomes in specific populations such as elite athletes, patients with borderline bone loss, or those with revision surgery. This lack of granularity limits the ability to provide nuanced recommendations tailored to individual patient needs.

Future Research Directions

Future research should aim to overcome these limitations through well-designed multicenter randomized controlled trials with standardized surgical protocols and outcome reporting. Such trials would provide higher-level evidence to definitively compare remplissage and Latarjet across varied clinical scenarios. Longer follow-up studies are also necessary to evaluate the impact of each procedure on long-term joint preservation, particularly the development of degenerative changes.

In addition, future investigations should stratify outcomes by sport type and competitive level to better inform recommendations for athletes. Given the growing emphasis on patient-reported outcomes, studies incorporating sport-specific functional scores and psychological readiness assessments may provide more clinically relevant data than traditional PROMs alone. Economic analyses comparing implant costs, operative time, and complication-related revisions would also add value, especially in healthcare systems where cost-effectiveness is a critical factor.

CONCLUSION

Both arthroscopic Bankart repair with remplissage and the Latarjet procedure provide reliable stabilization and meaningful functional improvement for patients with recurrent anterior shoulder instability. Across the included studies,

recurrence rates were similarly low, and patient-reported outcomes improved substantially after either procedure. The major distinction lies in functional profile and complication risk. Remplissage carries a predictable but modest loss of external rotation, which may be relevant for overhead athletes, while the Latarjet preserves motion but is associated with a higher complication burden, including graft- and hardware-related problems.

These findings underscore that surgical choice should be individualized according to patient characteristics, athletic demands, and the extent of bone loss. Remplissage is well suited to cases with engaging Hill-Sachs lesions and subcritical glenoid bone loss, whereas Latarjet remains preferable in patients with critical bone defects, collision athletes, or failed prior stabilization. Future randomized trials with long-term follow-up are warranted to refine indications and clarify the role of remplissage in borderline or higher bone-loss scenarios.

Declaration by Authors

Ethical Approval: Not applicable

Acknowledgement: None

Source of Funding: None

Conflict of Interest: No conflicts of interest declared.

REFERENCES

1. Galvin JW, Ernat JJ, Waterman BR, Stadecker MJ, Parada SA. The Epidemiology and Natural History of Anterior Shoulder Instability. *Curr Rev Musculoskelet Med*. 2017 Dec;10(4):411–24.
2. Valencia Mora M, Ruiz-Ibán MÁ, Heredia JD, Diaz RR, Cuéllar R. Management of Humeral Defects in Anterior Shoulder Instability. *Open Orthop J*. 2017 Aug 31;11(Suppl-6, M18):1011–22.
3. Arciero RA, Parrino A, Bernhardson AS, Diaz-Doran V, Obopilwe E, Cote MP, et al. The Effect of a Combined Glenoid and Hill-Sachs Defect on Glenohumeral Stability: A Biomechanical Cadaveric Study Using 3-Dimensional Modeling of 142 Patients. *Am J Sports Med*. 2015 June;43(6):1422–9.

4. Provencher MT, Midtgaard KS, Owens BD, Tokish JM. Diagnosis and Management of Traumatic Anterior Shoulder Instability. *J Am Acad Orthop Surg.* 2021 Jan 15;29(2):e51–61.
5. Castagna A, Garofalo R, Conti M, Flanagan B. Arthroscopic Bankart repair: Have we finally reached a gold standard? *Knee Surg Sports Traumatol Arthrosc.* 2016 Feb;24(2):398–405.
6. Shaha JS, Cook JB, Song DJ, Rowles DJ, Bottoni CR, Shaha SH, et al. Redefining “Critical” Bone Loss in Shoulder Instability: Functional Outcomes Worsen With “Subcritical” Bone Loss. *Am J Sports Med.* 2015 July;43(7):1719–25.
7. Purchase RJ, Wolf EM, Hobgood ER, Pollock ME, Smalley CC. Hill-Sachs “Remplissage”: An Arthroscopic Solution for the Engaging Hill-Sachs Lesion. *Arthrosc J Arthrosc Relat Surg.* 2008 June;24(6):723–6.
8. Lazarides AL, Duchman KR, Ledbetter L, Riboh JC, Garrigues GE. Arthroscopic Remplissage for Anterior Shoulder Instability: A Systematic Review of Clinical and Biomechanical Studies. *Arthrosc J Arthrosc Relat Surg.* 2019 Feb;35(2):617–28.
9. Castropil W, Mauad JR, Amorim FHB, Bitar AC, Garofo AGP, Schor B. Decreased Surgical Duration, Less Complications, And Faster Return To Activities Across The Learning Curve For The Arthroscopic Latarjet Technique. *Acta Ortopédica Bras.* 2024;32(5):e277567.
10. Griesser MJ, Harris JD, McCoy BW, Hussain WM, Jones MH, Bishop JY, et al. Complications and re-operations after Bristow-Latarjet shoulder stabilization: a systematic review. *J Shoulder Elbow Surg.* 2013 Feb;22(2):286–92.
11. Boileau P, O’Shea K, Vargas P, Pinedo M, Old J, Zumstein M. Anatomical and Functional Results After Arthroscopic Hill-Sachs Remplissage. *J Bone Jt Surg.* 2012 Apr 4;94(7):618–26.
12. Camp CL, Dahm DL, Krych AJ. Arthroscopic Remplissage for Engaging Hill-Sachs Lesions in Patients With Anterior Shoulder Instability. *Arthrosc Tech.* 2015 Oct;4(5):e499–502.
13. Franceschi F, Papalia R, Rizzello G, Franceschetti E, Del Buono A, Panasci M, et al. Remplissage Repair—New Frontiers in the Prevention of Recurrent Shoulder Instability: A 2-Year Follow-up Comparative Study. *Am J Sports Med.* 2012 Nov;40(11):2462–9.
14. Blonna D, Bellato E, Caranzano F, Assom M, Rossi R, Castoldi F. Arthroscopic Bankart Repair Versus Open Bristow-Latarjet for Shoulder Instability: A Matched-Pair Multicenter Study Focused on Return to Sport. *Am J Sports Med.* 2016 Dec;44(12):3198–205.
15. Bessière C, Trojani C, Carles M, Mehta SS, Boileau P. The Open Latarjet Procedure Is More Reliable in Terms of Shoulder Stability Than Arthroscopic Bankart Repair. *Clin Orthop.* 2014 Aug;472(8):2345–51.

How to cite this article: Anak Agung Ngurah Arya Yugadhyaksa, Komang Mahendra Laksana, Anak Agung Yukta Panditama. Functional outcomes of arthroscopic Bankart repair with remplissage versus Latarjet procedure in recurrent anterior shoulder instability: a systematic review. *International Journal of Research and Review.* 2026; 13(3): 387-399. DOI: [10.52403/ijrr.20260344](https://doi.org/10.52403/ijrr.20260344)
