

Role of Enamel and Enamel Structure in Forensic Odontology- A Comprehensive Review

Dr. Nikita K. Sahu¹, Dr. Jigna R. Pathak², Dr. Shilpa Patel³,
Dr. Priyadarshani R. Sarkate⁴, Dr. Rashmi V. Hosalkar⁵, Dr. Manasi S. Kale⁶

¹Postgraduate Student, Dept. of Oral Pathology and Microbiology, MGM DCH, Navi-Mumbai

²Professor, Dept. of Oral Pathology & Microbiology, MGM's Dental College & Hospital, Navi-Mumbai

³Professor & Head, Dept. of Oral Pathology & Microbiology, MGM's Dental College & Hospital, Navi-Mumbai

⁴Postgraduate Student, Dept. of Oral & Maxillofacial Surgery, MGM's Dental College & Hospital, Navi-Mumbai

⁵Lecturer, Dept. of Oral Pathology & Microbiology, MGM's Dental College & Hospital, Navi-Mumbai.

⁶Postgraduate Student, Dept. of Oral & Maxillofacial Surgery, MGM's Dental College & Hospital, Navi-Mumbai

Corresponding Author: Dr. Nikita K. Sahu

DOI: <https://doi.org/10.52403/ijrr.20260583>

ABSTRACT

Ethnologic identification is one of the majority demanding subjects to facilitate human has been encountered with. The Forensic magnitude of dental tissue has been well predictable since of the details that tooth is hardest of all human tissues and conserved undamaged for an extensive episode of instance following fatality. They are constant chemically and they retain their characteristic; it becomes consistent source for determination of human identification. The study of tooth print for the rationale of establishing the individuality of a victim is called amelogyphics. Tooth prints are unique to an individual and can be used as a valuable inexpensive tool in forensic odontology for personal identification. This is more detailed and reliable if more than one technique is applied. Each human being possesses unique dental tooth print which makes them aid in identification. Through the ages, odontological examinations have been a critical determinant in the search of human identity. This piece of review writing gives an

overview on role of enamel and enamel structure in forensic odontology.

Keywords: enamel; forensic; odontology; personal; identification; ante-mortem.

INTRODUCTION

The term "Forensic" was derived from the Latin word *forensis*, which means "appertain to the forum". According to Jones, in ancient Rome the forum was a public square where trials and debates were held and consequently served as a court of law. Odontology refers to the study of teeth and in effect denotes dentistry. Forensic odontology or Forensic dentistry was defined by the Federation Dentaire Internationale (FDI) as 'that branch of dentistry, which in the interest of justice, deals with the proper handling and examination of dental evidence, and with the proper evaluation and presentation of dental findings'[1]. Forensic odontology plays a key role in identification in natural calamities such as earthquakes, floods and tsunami, and accidental or man-made events such as airplane crashes or terrorist attacks that result in multiple fatalities that are difficult to

identify by conventional methods like visual recognition or fingerprints. It largely deals with post-mortem identification based on detection of distinctive oral and perioral features present of an individual [1,2].

In recent times, forensic odontology has evolved as a separate specialty and has established itself as an indispensable tool in medico legal and criminal matters, in particular in personal identification, age estimation and gender determination [3].

Forensic odontologists delve into the following [1]:

- Identifying unknown human remains through comparison of post-mortem dental evidence with dental records of the presumed deceased
- Assisting at the scene of a mass disaster and in the deceased identification
- Eliciting the ethnicity/ population affinity and assisting in building up a picture of lifestyle and diet of skeletal remains at forensic and archaeological sites
- Assessing the sex of skeletonized remains
- Age estimation in both the living and dead
- Analysis and investigation of bite marks, found on human tissue, animal tissue, and inanimate objects/ foodstuffs
- Presenting evidence in court of law as expert witness.

The different methods employed in forensic odontology consists of cheiloscopia (lip prints), rugoscopy (palatal rugae), bite marks, radiographs, photographic study, and molecular methods. These methods have limitations and are less efficient when bodies are brutally mutilated, burned or charred [4]. Teeth have been extensively used as a source of information in such cases, especially when the soft tissue cannot provide reliable information.

As dental enamel is the hardest tissue in the human body, it has the highest resistance to most environmental effects like fire, desiccation, and decomposition as well as post-mortem changes [5]. Here an attempt has

been made to emphasize the various ways in which, enamel can be used as a personal identification aid in forensic odontology.

Enamel Rods or Prisms

Dental enamel is produced by ameloblasts which are derived from the ectoderm. The fundamental structural unit of enamel are the rods (prisms) and interrod enamel (interprismatic substance) [6,7]. The enamel formation is an exceedingly organized process, in which the ameloblasts produce enamel rods in an undulating and intertwining path. The term 'tooth print' is used to describe the enamel rod end pattern. The study of patterns of enamel rods is known as "Amelogyphics" (amelo-enamel, glyphics-carvings) [8].

Enamel rods measure about 9 μm in length and 5 μm in breadth. They generally have a clear crystalline appearance, thus, permitting light to pass through them. They seldom appear hexagonal, round or oval in cross-section underneath the light microscope [6].

Sometimes this cross-sectional view of human enamel, may bear a resemblance to fish scales. Recently, confocal laser scanning microscopy was used to study the reconstructed 3D images of the path of a single and groups of rods. It was observed that the rods did not maintain the same outline throughout. Arcade outlines were seen near dentinoenamel junction whereas keyhole shaped outlines were seen at the enamel surface. Keyhole- or paddleshaped prism patterns in human enamel are well appreciated through electron microscopy [8]. Following are the three main patterns using electron microscopy achieved by the shape of enamel prisms [2] (Figure1):

- Pattern I: Circular Prisms.
- Pattern II: Alignment of prisms in parallel rows.
- Pattern III: Prisms are arranged in staggered rows such that the tail of prism

lies between two heads in the next row, giving a key whole appearance.

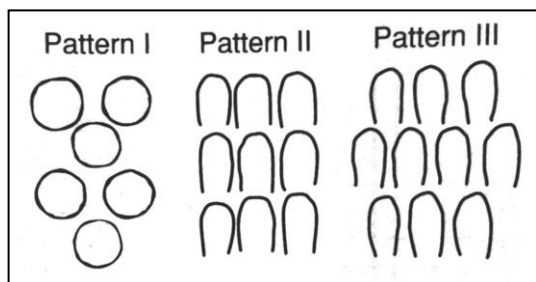


Figure 1: Patterns of enamel prisms

Types of Enamel Rod End Patterns [8] (Figure 2)

- Wavy branched
- Wavy un-branched
- Linear branched
- Linear un-branched
- Whorl open
- Whorl closed
- Loop (L)
- Stem Like




Figure 2: Distinct sub-patterns observed in tooth prints. A) wavy branched B) wavy un-branched C) linear branched D) linear unbranched E) whorl-open F) whorl-closed G) loop H) stem-like.

Methods Used in Recording Enamel Rod End Patterns [2,8,9]

In enamel tooth print, recording of rod endings on tooth surface is proceeded using acid etchant, acetate peel technique, cellophane tape, rubber base impression materials and automated biometrics as sequential steps for reproducing complete and accurate enamel rod end patterns for personal identification.

1. Acid etching

The acid etching on the surface of enamel results in the elimination of the surface

mineral constituent in the rod and rod sheath. As the rods and rod sheaths have a diverse mineral density, the etching results in an irregular dissolution of the surface enamel along with the elimination of the smear layer. The most commonly used acid for etching is 10% orthophosphoric acid in gel form. Following are the three types of etch patterns can be obtained:

1. Predominant dissolution of prism cores.
2. Predominant dissolution of prism peripheries.
3. No prism structure is evident.

2. Acetate Peel Technique

‘Peel’ is a replica of an acid etched mineral surface, made on acetate film. The technique of peel making was first developed by palaeobotanists to study the cellular structures of fossil plants. The human teeth to be analyzed should be scaled and polished. The middle third of the facial/labial surface of tooth is selected because it is resistant to changes due to attrition, erosion and abrasion. 37% orthophosphoric acid for 20 seconds, needs to be etched on surface, then washed with water and dried. Apply a thin layer of acetone over a small piece of cellulose acetate film and positioned directly over the etched surface of the tooth without any finger pressure for 20 minutes. The acetone dissolves a layer of cellulose acetate, and the dissolute settles down along the irregularities on the enamel surface. The film is gently peeled after 20 minutes and observed under light microscope. This technique reproduces the same pattern and sub-patterns of enamel rod endings in subsequent imprints taken from the same area of the same tooth.

3. Cellophane Tape Technique

A portion of extended cellophane tape is to be applied over the surface of tooth with no finger pressure by using small piece of cotton roll and then applied over the same for better adaption of the cellophane tape. The cellophane tape is then directly pulled off lightly and placed on a clean glass slide and observed under light microscope.

4. Rubber-Base Impression Material Technique

The rubber impression material include catalyst and base of light body needs to be equally mixed for suitable consistency and directly placed on the conditioned surface. Light body type impression material is used due to its thin consistency and less viscosity, which helps record even minor details more accurately. After the setting of the impression

material, the replica is suspiciously peeled and positioned over clean glass slide and then observed under the stereomicroscope (because rubber-base impression material is not a translucent material to view under light microscope).

5. Biometric Analysis

The term “biometrics” refers to detection techniques which are based on specific physical characteristics. It is a technology of identification or verification of a person which transforms a biological, morphological or behavioral characteristic in a digital value. Verification methodology and biometric based recognition methods like fingerprint verification, iris scanning, and facial recognition have been steadily improved and developed in automated systems and softwares, which have the ability to differentiate persons reliably. VeriFinger® standard SDK version 6.7 software used to recognizes the patterns of enamel rod endings as series of lines running in varying directions [10]. When the patterns studied are consistently recognized and provide greater confidence, they are referred to as positive identification.

Uses of Enamel Rods

Enamel rod end patterns are unique for each tooth in an individual and may be used as an adjunct with other methods for personal identification. Wavy branched pattern was found to be predominant pattern in incisors, canines and first premolars [10].

Advantages of Tooth Print

- This technique is simple and inexpensive.
- Rapid method which can be performed by even a dental auxiliary staff.
- Usually, this method of personal identification can be included as adjunct ante-mortem dental records of fire fighters, soldiers, jet pilots, divers, and

people who live or travel to politically unstable areas.

Disadvantages of tooth print

- Tooth print record must be updated at least every 4 years to overcome the enamel loss due to wear and tear [10].
- Course of enamel rods is not the identical throughout the thickness of enamel. Therefore, theoretically the enamel rod end pattern should differ at varying depths of enamel [12].
- Tooth prints are unique to a tooth but they show intra and inter individual dissimilarities [12].

Table 1: Hidden Treasure of Enamel in Human Identification [11].

Enamel Structure			
Structure	Description	Use	Methodology
Neonatal line	They are present in both enamel and dentine of deciduous teeth and permanent first molars which indicate the development during the transitional period between intrauterine and extra uterine environments. So the neonatal line can be used to assess the amount of pre and post-natal enamel formation.	Age Assessment	Ground section
Incremental lines	Incremental lines of Retzius are caused by variation in the rhythmic mineralization of enamel prisms. This rhythmic pattern may be altered by various external factors such as metabolic disturbances so that the lines may appear closer or the rest periods may be prolonged.	Age Assessment	Ground section
Hunter schreger bands	Hunter Schreger bands in enamel have been observed to closely resemble a fingerprint as they form minuitiae (points at the ending lines and at bifurcations when one line splits into two). Hence they have also been referred to as toothprints.	Personal Identification	Biometric Based Method
Enamel protein	DNA analysis through AMEL gene used to identify the sex of the individual. Male contain two different AMEL genes, one on X chromosome and one on Y chromosome, whereas female has two identical genes on X chromosome. Thus AMEL gene that encodes for female amelogenin is located on X chromosome and for male is located on Y chromosome.	Sex determination	DNA analysis

Table.2 Details of Research Work Depicting the Role of Tooth Print in Personal Identification [13,14,15,16].

Sr. No	Authors	Material	Methodology	Inferences
1	J Naziya et al 2019	Maxillary central incisor, canine and first premolar were selected from 100 different families.	Acetate peel technique	Familial tendency of tooth print pattern in incisors, canines and premolars was noticed in 65%, 66% and 52% of the families, respectively.
2	Vineetha Christopher et al 2017	Upper first premolars were recorded from 80 individuals.	Acid Etching Using Cellulose Acetate Strips.	Pattern of tooth print differed between individuals for the same tooth though maintaining the site specificity.
3	Joshi Priya Shirishl et al 2014	30 Maxillary central incisor, lateral incisor and canine were collected from different individuals & some from same individuals for inter-individual & intra-individual comparison.	Acetate peel technique	None of the 30 tooth prints obtained showed distinct similarity to each other. Tooth prints obtained from different individuals were dissimilar. Similarly tooth prints obtained from same individuals were also dissimilar.
4	Raju G.S et al 2014	30 freshly extracted teeth	Acid Etching Using a	Samples showed definite enamel rod end patterns which were specific for an

			Cellophane Tape	individual and also specific for a tooth.
5	Nidhi Gupta et al 2009	Incisors, Canines, Premolars and Molars	Acid Etching Using a Cellophane Tape	Comparison of tooth prints from different individuals (incisors with incisors; canines with canines; premolars with premolars, molars with molars) and from same individuals (incisors with incisors; canines with canines; premolars with premolars, molars with molars) was also dissimilar
6	Manjunath et al. 2008	30 maxillary right central incisor, canine and first premolar were analyzed.	Acetate Peel Technique and Automated Biometrics.	None of the 30 tooth prints obtained showed distinct similarity to each other. Comparison of tooth prints obtained from different individuals (incisor with incisor; premolar with premolar) and from same individuals (incisor with incisor; premolar with premolar) showed to be dissimilar.

CONCLUSION

Dental structures are hard, stable and unique remains unchanged if body is disfigured or mutilated due to manmade or natural mass disasters. Tooth prints/ Amelogyphics is a novel part and emerging tool of research in the field of forensic odontology. Enamel covers the tooth crown, is the hardest biological hard tissue and highly mineralized, therefore, withstands both shearing and impact forces. Enamel rod end patterns are unique for each tooth in an individual and may be used as an adjunct with other methods for personal identification. The surface of enamel is always subjected to micro- and macro wearing through abrasion, attrition and erosion. The effect of these processes on the pattern of enamel rod ends needs to be determined. Theoretically the enamel rod end pattern should vary at varying depths of enamel, which needs to be verified by further studies. Even though tooth prints, are unique to an individual tooth, the value of it as a tool in forensic science for personal identification lies in its reproduction and permanency.

Declaration by Authors

Acknowledgement: None

Source of Funding: None

Conflict of Interest: No conflicts of interest declared.

REFERENCES

1. Rajenderan R, Sivapathasundaram B. Shafer's Textbook of Oral Pathology. Elsevier Publications. 6th edition 2009.
2. Dinkar D et al. Amelogyphics- A Mirror within You. Austin J Forensic Sci Criminol. 2018; 5(1): 1075.
3. Rakesh N. et al. Reliability of Amelogyphics for Person Identification Following Adverse Conditions. Journal of Dental & Oro-facial Research, Jan. 2018; Vol. 14: Issue 01.
4. American Board of Forensic Odontology (ABFO). Body Identification Information & Guidelines; Revise February 2017.
5. Shanbhag V K. Significance of Dental Records in Personal Identification in Forensic Sciences. Journal of Forensic Science and Medicine, January 2016; Volume 2: Issue 1.
7. Kumar G S. Orban's Oral Histology and Embryology. Elsevier a Division of Reed Elsevier India Private Limited. 13th edition, 50:93.
8. Nanci A. Ten Cate's Oral Histology 8th Edition, 122:164.
9. Sha S K. et al. Are Tooth Prints a Hard Tissue Equivalence of Finger Print in Mass
10. Disaster: A Rationalized Review. Journal of Pharmacy and Bioallied Sciences November 2019; 106.209: 162.61.
11. Deshmukh R A. Need for Newer Techniques for Personal Identification. Journal of Forensic Research, March 2015, 6:3.

12. J Naziya et al. Analysis of enamel rod end pattern for personal identification. Journal of Oral and Maxillofacial Pathology, January-April 2019; Volume 23: Issue 1.
13. Chandrashekar C, Takahashi M and Miyakawa G. Enamel and Forensic Odontology - Revealing the Identity. J.Hard Tissue Biology, 2010 ;1-4:19(1).
14. Joshi PS and Bhosale SS. Study of Enamel Rod End Patterns for personal identification. Int J Dent Med Res, NOV - DEC 2014; VOL 4: ISSUE 4.
15. Manjunath K, Sriram G, Saraswathi TR, Sivapathasundharam B. Enamel rod end patterns: A preliminary study using acetate peel technique and automated biometrics. J Forensic Odontology 2008; 1:33-6.
16. Gupta N, Jadhav K, Ahmed Mujib BR, Amberkar VS. Is re-creation of human identity possible using tooth prints? An experimental study to aid in identification. Forensic Sci Int 2009; 192:67-71.
17. Christopher V. Can dead man tooth do tell tales? Tooth prints in forensic identification. J Forensic Dent Sci. 2017 Jan-Apr; 9(1): 47.
18. Sugunakar, Raju G.S., et al. Amelogyphics-- can it aid in forensic identification. Indian Journal of Dental Advancements, Gale Academic Onefile, Accessed 2014;4-6.

How to cite this article: Nikita K. Sahu, Jigna R. Pathak, Shilpa Patel, Priyadarshani R. Sarkate, Rashmi V. Hosalkar, Manasi S. Kale. Role of enamel and enamel structure in forensic odontology- a comprehensive review. *International Journal of Research and Review*. 2026; 13(5): 824-830. DOI: <https://doi.org/10.52403/ijrr.20260583>
